Dermatopathology Review

Shachar Sade

Sunnybrook Health Sciences Centre

University of Toronto LMP

Sunnybrook
HEALTH SCIENCES CENTRE

Laboratory Medicine & Pathobiology
UNIVERSITY OF TORONTO

Disclosure Statement – Shachar Sade

- I have no financial relationships to disclose.

AND

- I will not discuss off label use and/or investigational use in my presentation.

Objectives

- General outline for topics in dermatopathology
  - Start with an ability to recognize / diagnose some of the most common neoplastic skin lesions (with case examples)
  - Focus on common DDx dilemmas and useful practice points / pitfalls
- Have an approach to melanocytic lesions and understand synoptic reporting elements for melanoma.
- Introductory approach to inflammatory dermatopathology
  - Be able to diagnose the archetypes for 4 common inflammatory patterns of the skin

General outline

- Dermatopathology
  - Neoplasia
  - Inflammatory
  - Other
- Neoplasia in skin
  - Primary vs Secondary
  - Primary
    - Epidermal tumours
    - Adnexal tumours
    - Melanocytic tumours
    - Soft tissue tumours
      - Fibrohistiocytic, Vascular, Neural, Smooth muscle, Fat, other
    - Hematopoietic / lymphoid tumours
    - Non – neoplastic tumoural lesions

Practice point

- Skin lesions are common, easily detected and easily accessed / biopsied / removed, and so, are common general surgical pathology specimens
- The vast majority of cutaneous tumoural lesions biopsied or removed are easily diagnosed tumours with characteristic histopathological features!

Consultation cases

1. Melanocytic lesions
2. Epithelial tumours especially adnexal tumours
   - Poor recognition and variable / mixed histology
3. Mesenchymal tumours / Undifferentiated tumours
   - Poor recognition; Relatively undifferentiated histology; Histologic variants
4. Inflammatory disorders
   - Poor recognition; Wide DDx; Clinico-pathologic correlation; Often STAT cases +/- DIF
5. Dense or atypical hematolymphoid infiltrates

1 – Common cutaneous neoplasms

20 common neoplastic lesions in skin:

1. Fibroepithelial polyp ("Skin tag")
2. **Benign melanocytic nevi**
3. **Seborrheic keratosis**
4. **Epidermoid cyst**
5. **Pilar cyst**
6. **Verruca vulgaris**
7. Scar / Keloid
8. **Actinic keratosis**
9. **Basal cell carcinoma**
10. Squamous cell carcinoma
11. Bowen's disease
12. Angiofibroma ("Fibrous papule")
13. **Dermatofibroma**
14. **Lentigo (solar, simple)**
15. Cherry angioma
16. Pyogenic granuloma
17. Lipoma / Angiolipoma
18. **Neurofibroma**
19. Ganglion cyst
20. Nevus lipomatosus superficialis

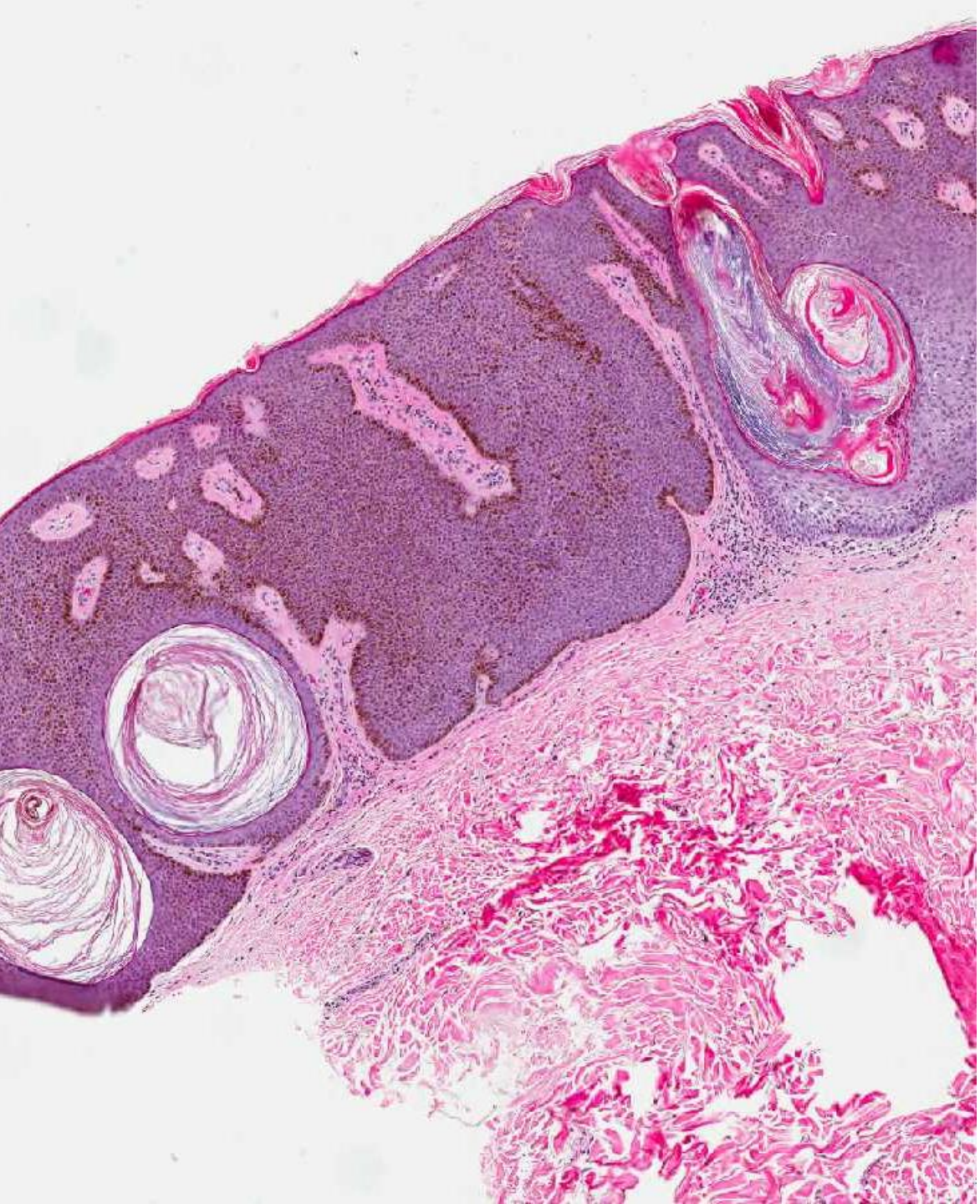

<u>Seborrheic keratosis</u>:
- Common
- Benign epidermal lesion
- Multiple histological subtypes

<u>Histology</u>:
- Acanthosis and hyperkeratosis
- No dysplasia
- May be irritated and show reactive changes

<u>Practice points</u>:
Don't miss a Bowen's disease
Don't overcall reactive changes (i.e. "Irritated SK")
Clinical correlation to consider possible DDx: Acanthosis nigricans, Epidermal nevus, Reactive epidermal hyperplasia

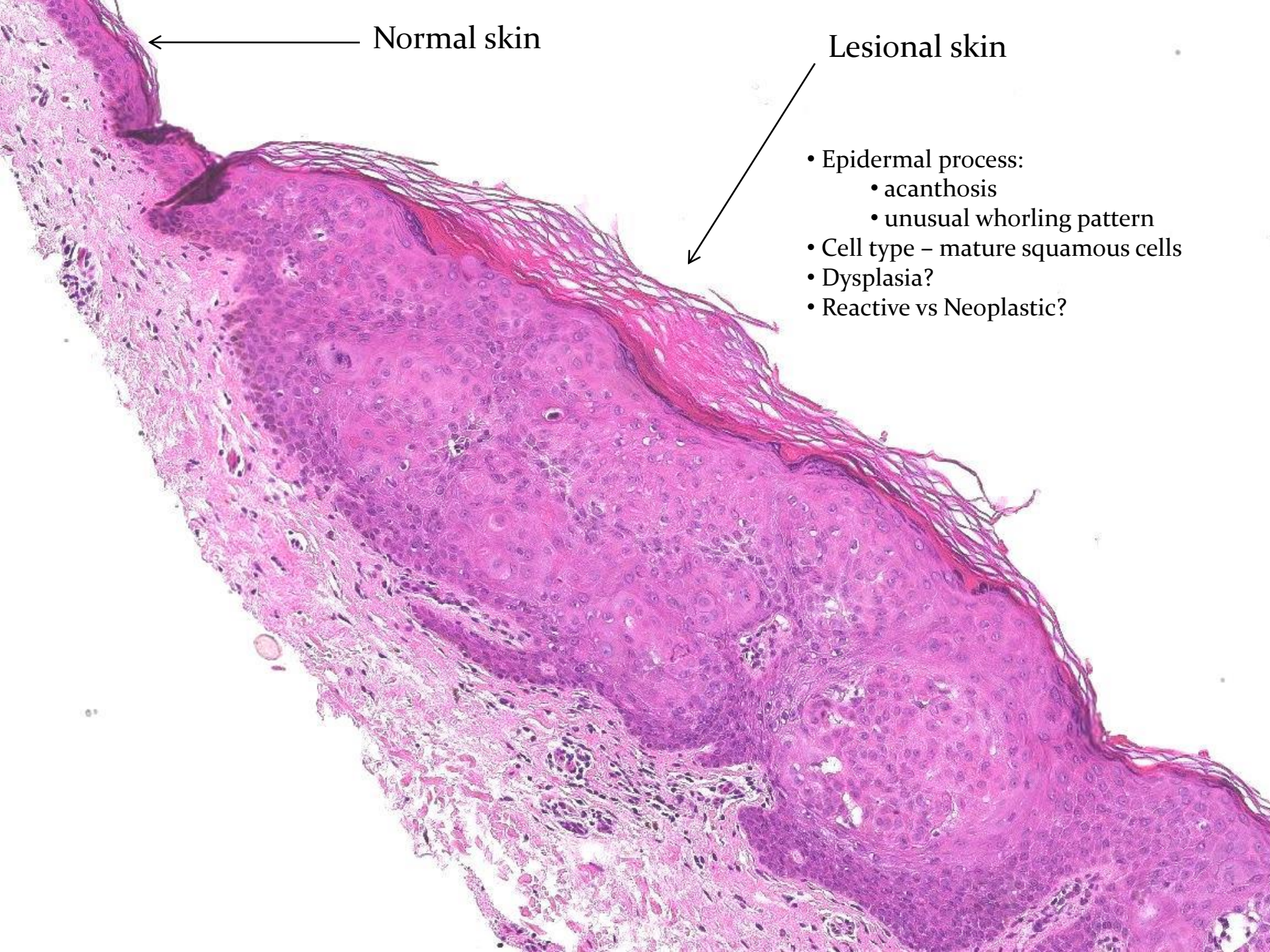
Normal skin
Lesional skin
• Epidermal process:
• acanthosis
• unusual whorling pattern
• Cell type – mature squamous cells
• Dysplasia?
• Reactive vs Neoplastic?

Borst-Jadassohn phenomenon

- Unique histological pattern of intraepidermal nests or whorls of basaloid or squamous cells
- May be seen in many epidermal lesions:

SK, VV, AK, Bowen's, Hidracanthoma simplex

- No clinical significance

Case 2

Clinical information:

42 M, leg

“enlarging atypical lesion”

Excision

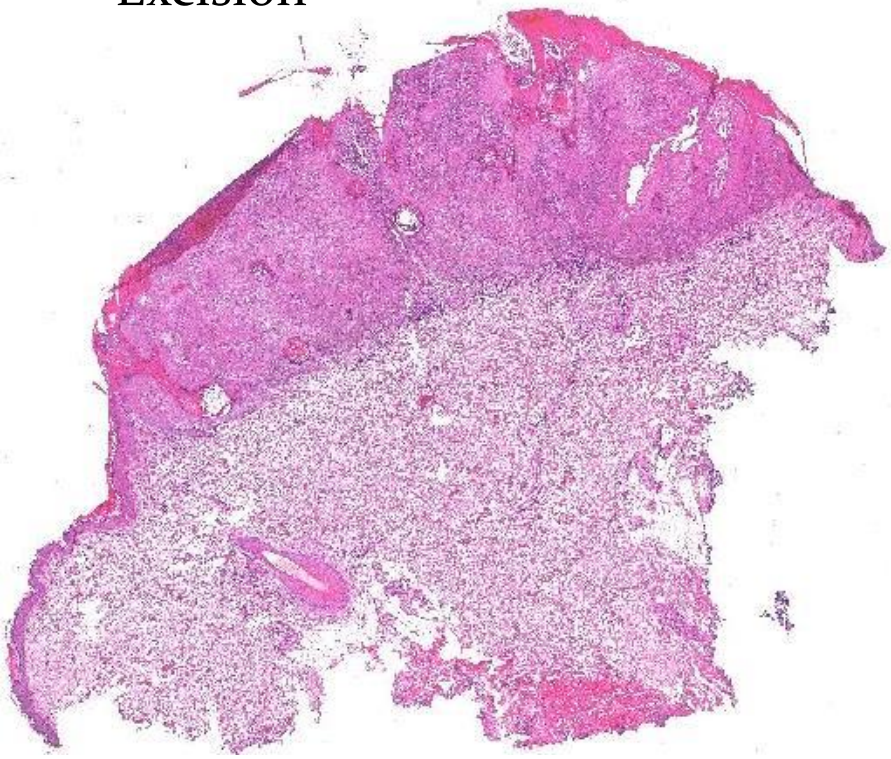

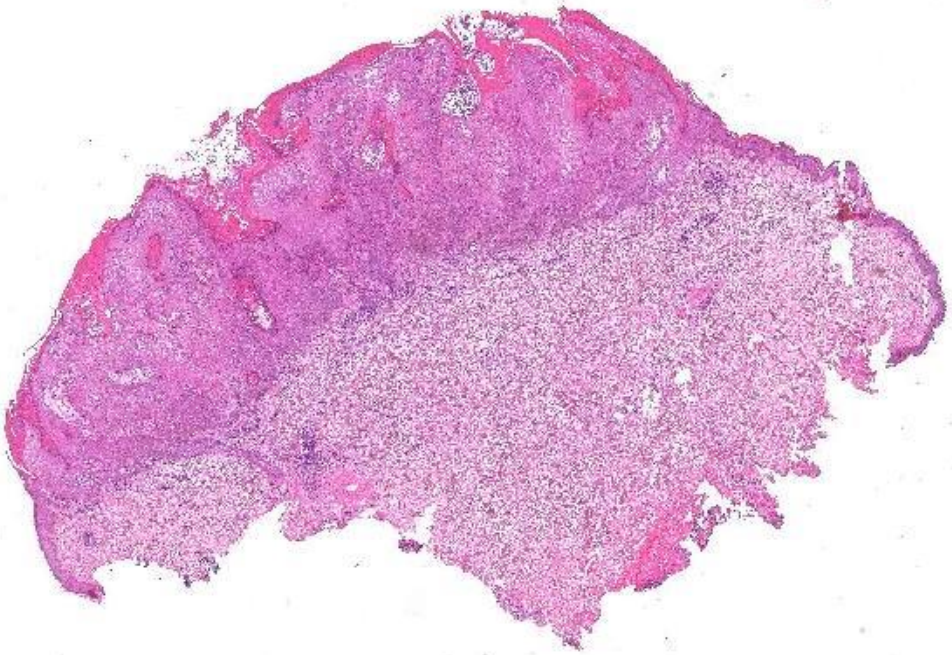

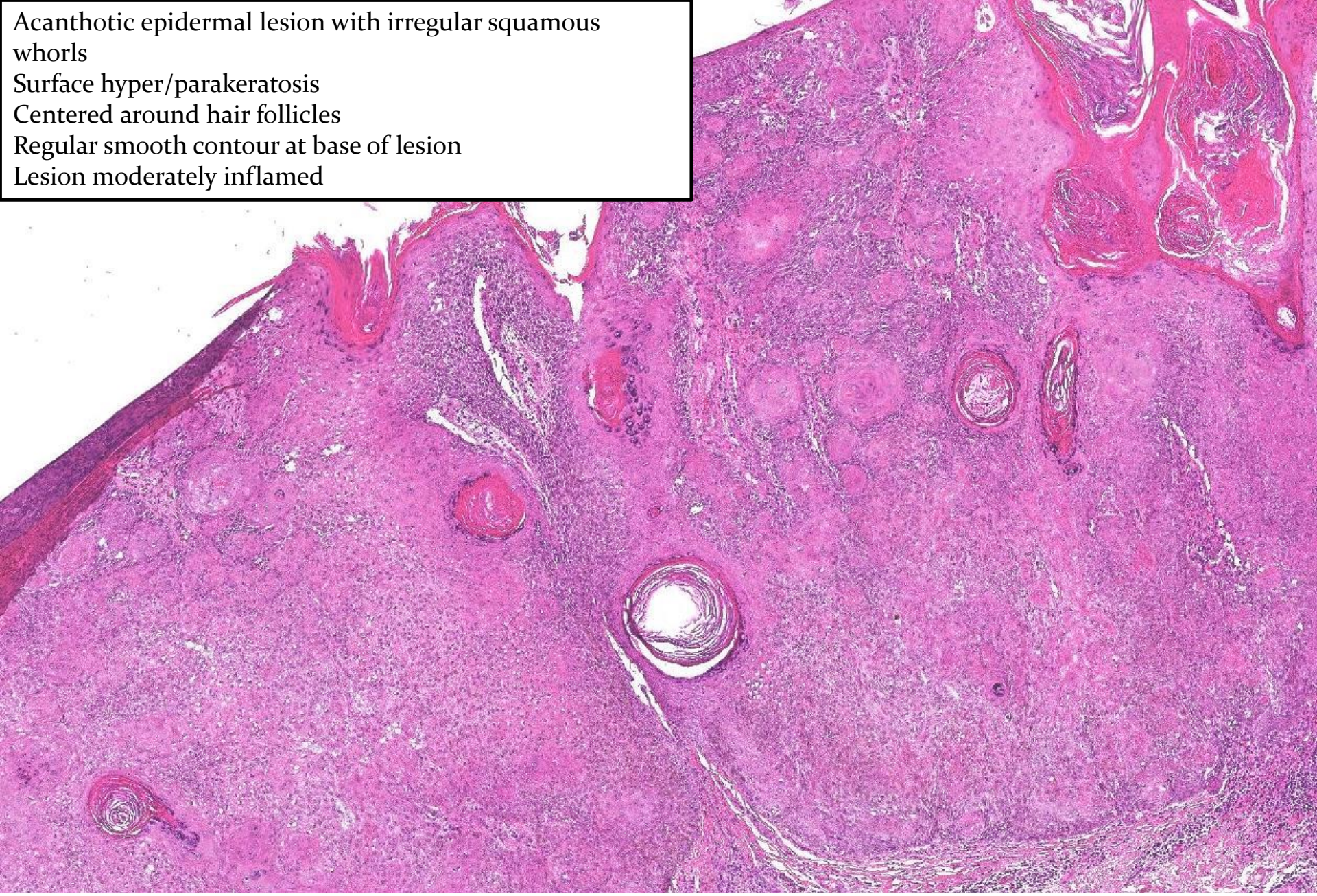
Acanthotic epidermal lesion with irregular squamous whorls
Surface hyper/parakeratosis
Centered around hair follicles
Regular smooth contour at base of lesion
Lesion moderately inflamed

Cellular atypia?

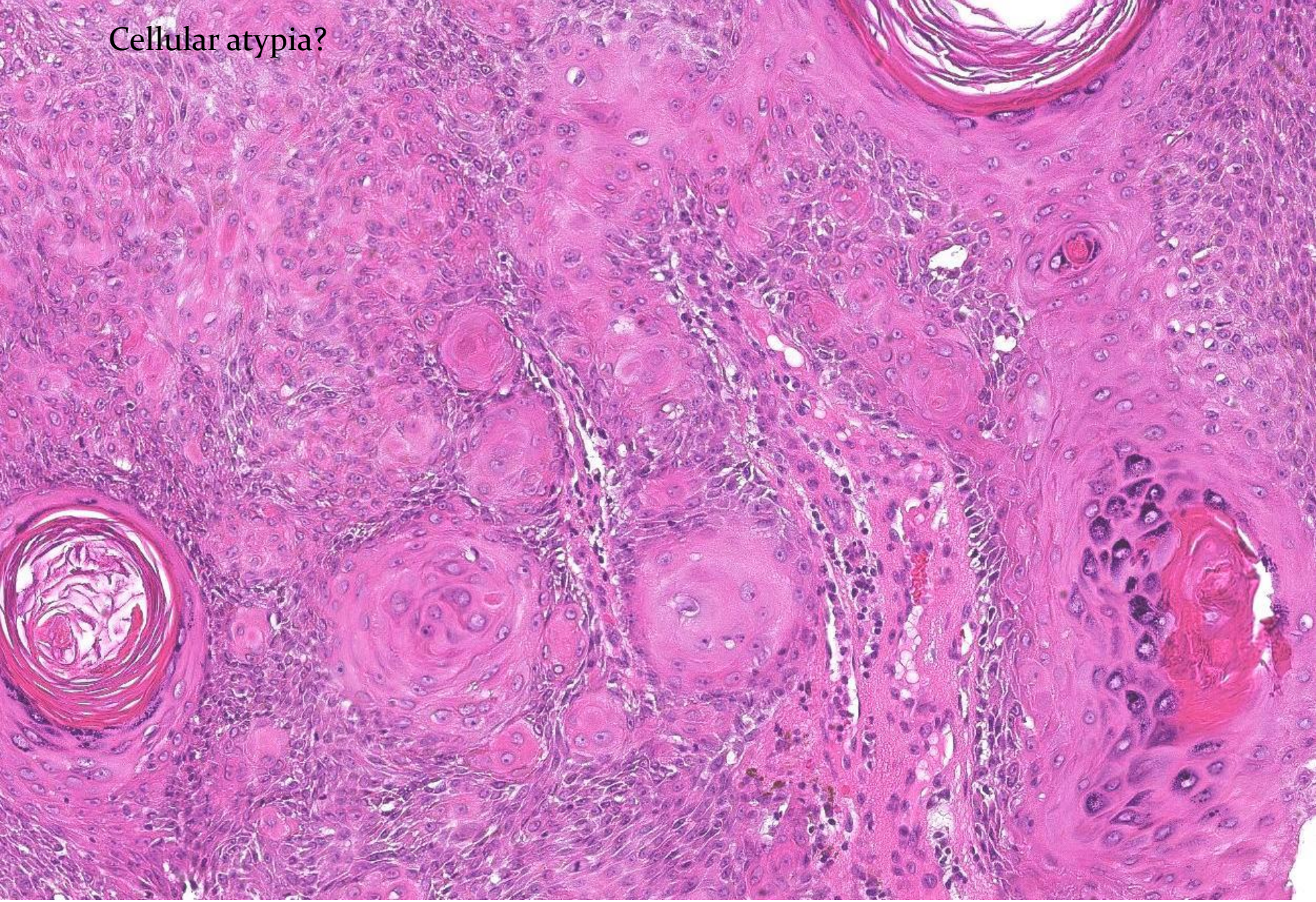

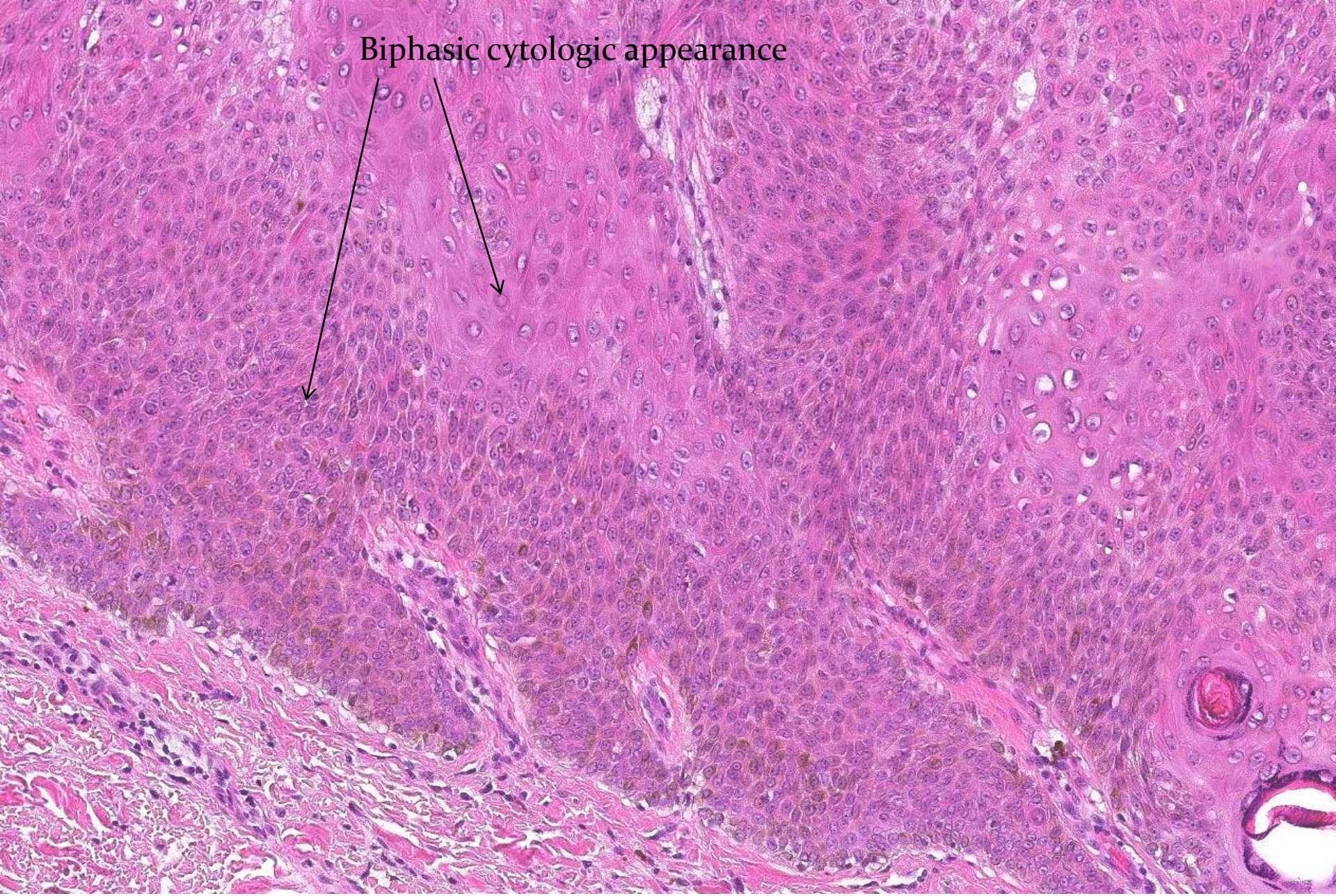
Biphasic cytologic appearance

Dysplasia vs Reactive atypia

	Reactive	Dysplasia
Cell size	Normal to modest enlargement	Usually enlarged
N:C ratio	Normal	Increased
Nuclei	Normal chromasia and chromatin Smooth nuclear membranes	Hyperchromatic and coarsening of chromatin Pleomorphism and nuclear membrane irregularities
Mitoses	Mild to moderate increase but basally oriented	Increased, Atypical, all levels
Nucleoli	Present – slight enlargement, multiple	Often absent
Maturation	Normal	Altered
Background	Inflamed	May or may not be inflamed
Clinical context	Setting suspicious for reactive	Setting suspicious for dysplasia

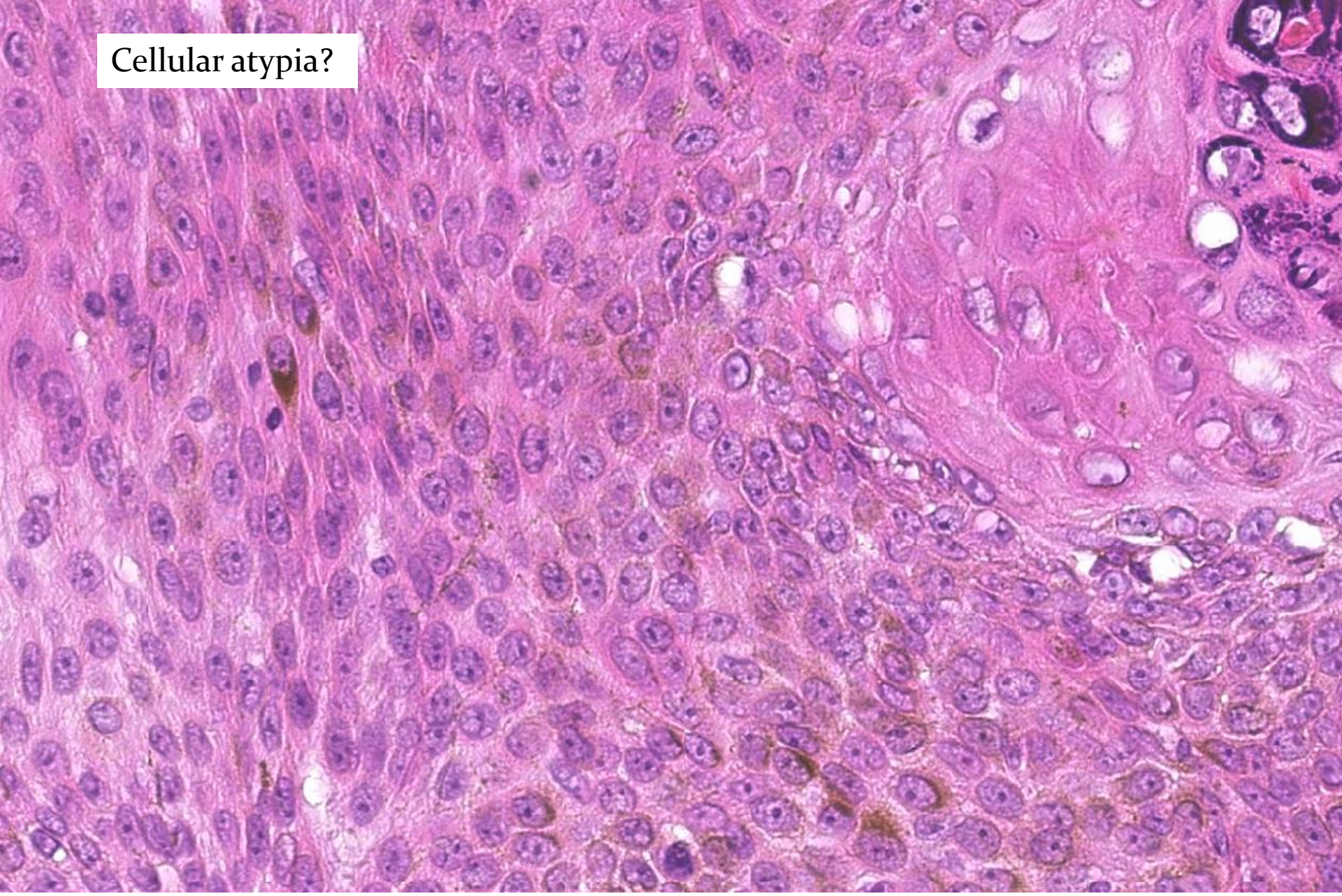
Cellular atypia?

Diagnosis and Message

Dx = Irritated SK / Inverted follicular keratosis

Message:

- Avoid pitfalls – reactive atypia
- Look for precursor lesion

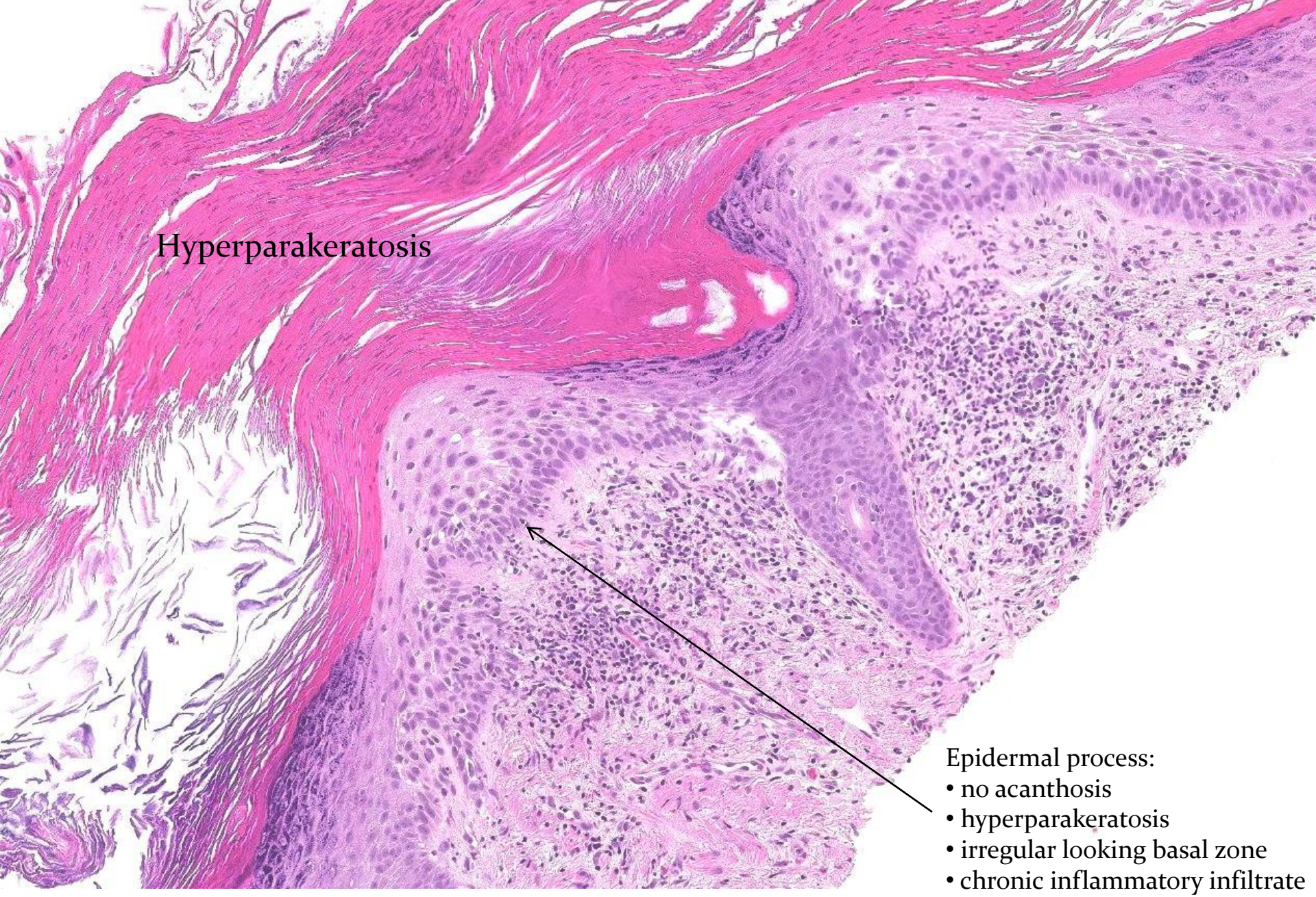

Epidermal process:
- no acanthosis
- hyperparakeratosis
- irregular looking basal zone
- chronic inflammatory infiltrate
- solar elastosis

Seborrheic keratosis

Hyperkeratotic subtype

Irritated subtype
(Inverted follicular keratosis)

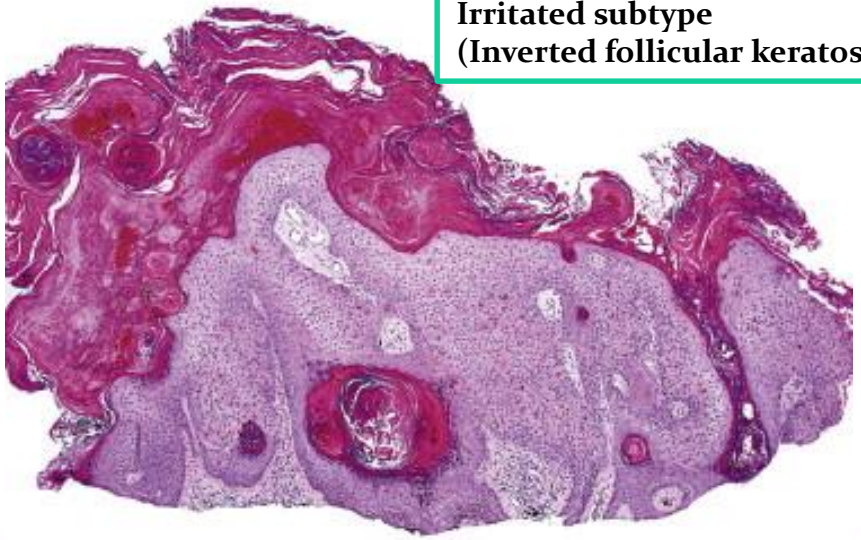

Reticulated (adenoid) subtype
Pigmented subtype

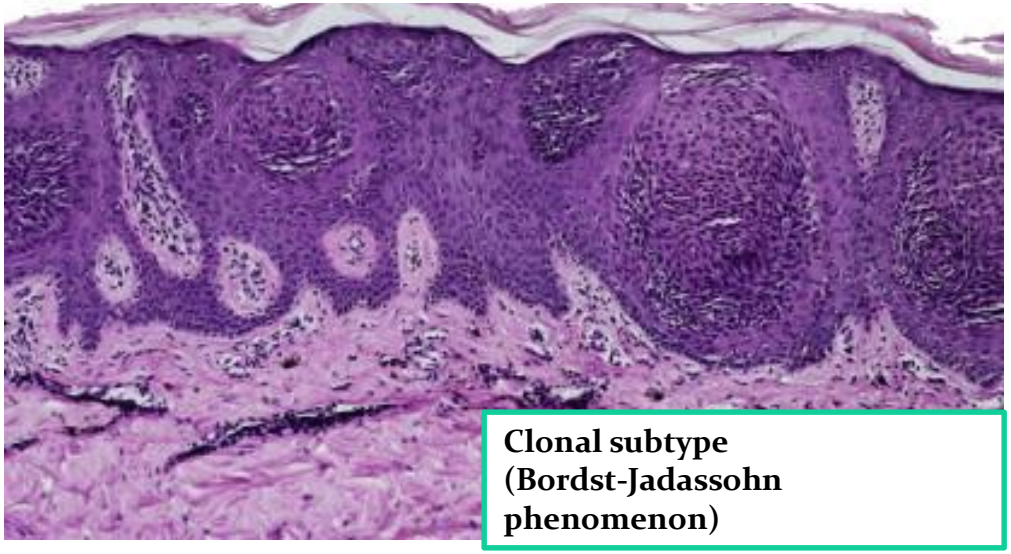

Clonal subtype
(Bordst-Jadassohn phenomenon)

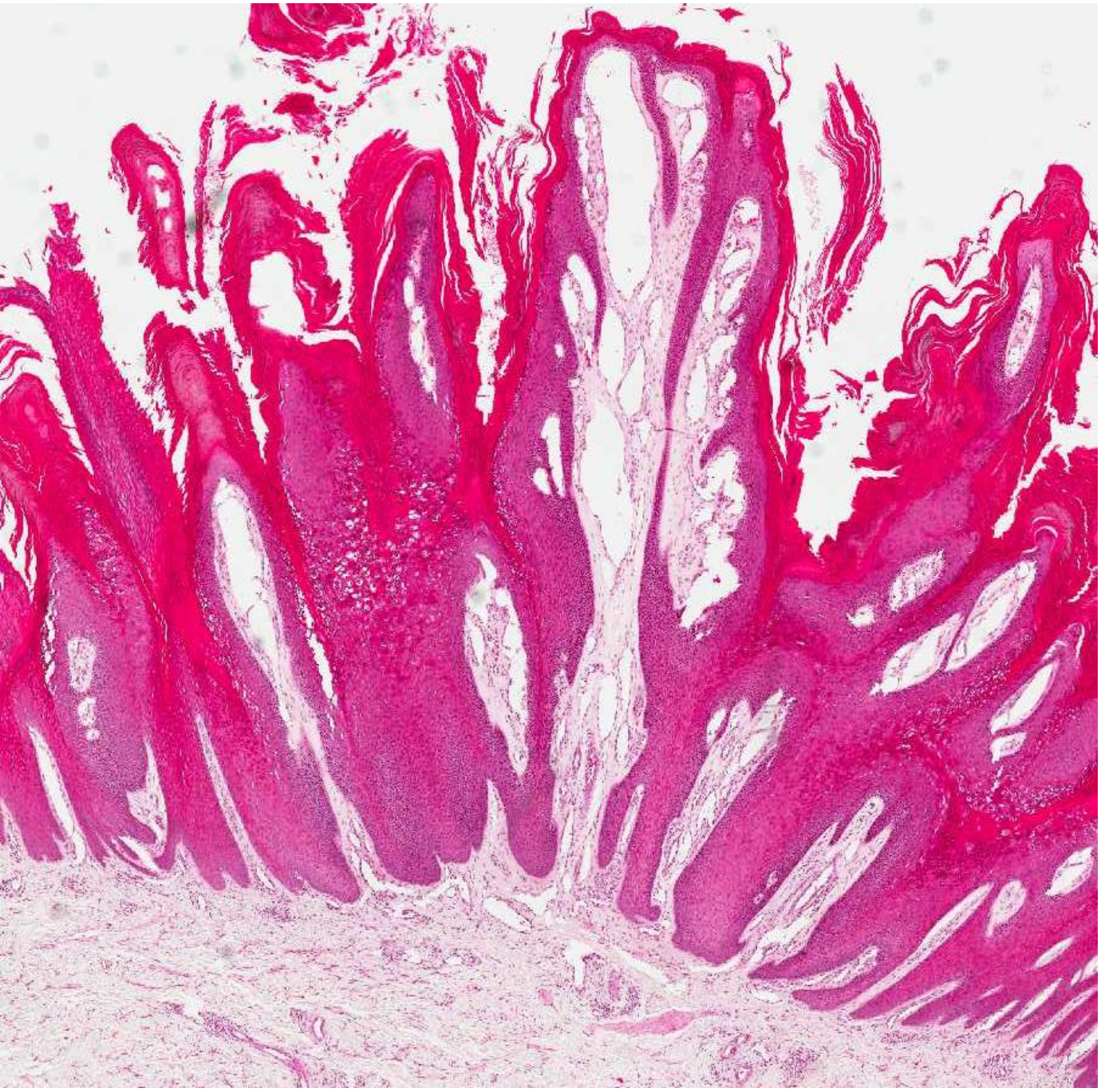

Verruca vulgaris:
- Common
- Benign epidermal lesion

Histology:
- Mainly papillomatosis and hyperkeratosis
- Rete ridges curve inwardly
- Columnar parakeratosis over papillary tips and coarse hypergranulosis at the base
- Dilated capillaries in dermal papillae and variable inflammation
- May show koilocytosis
- May be flat (Verruca plana)

Other papillomatous DDx:

Bowen;s disease
HAK

Acanthosis nigricans
Epidermal nevus / NSJ
CARP
LSC / PN

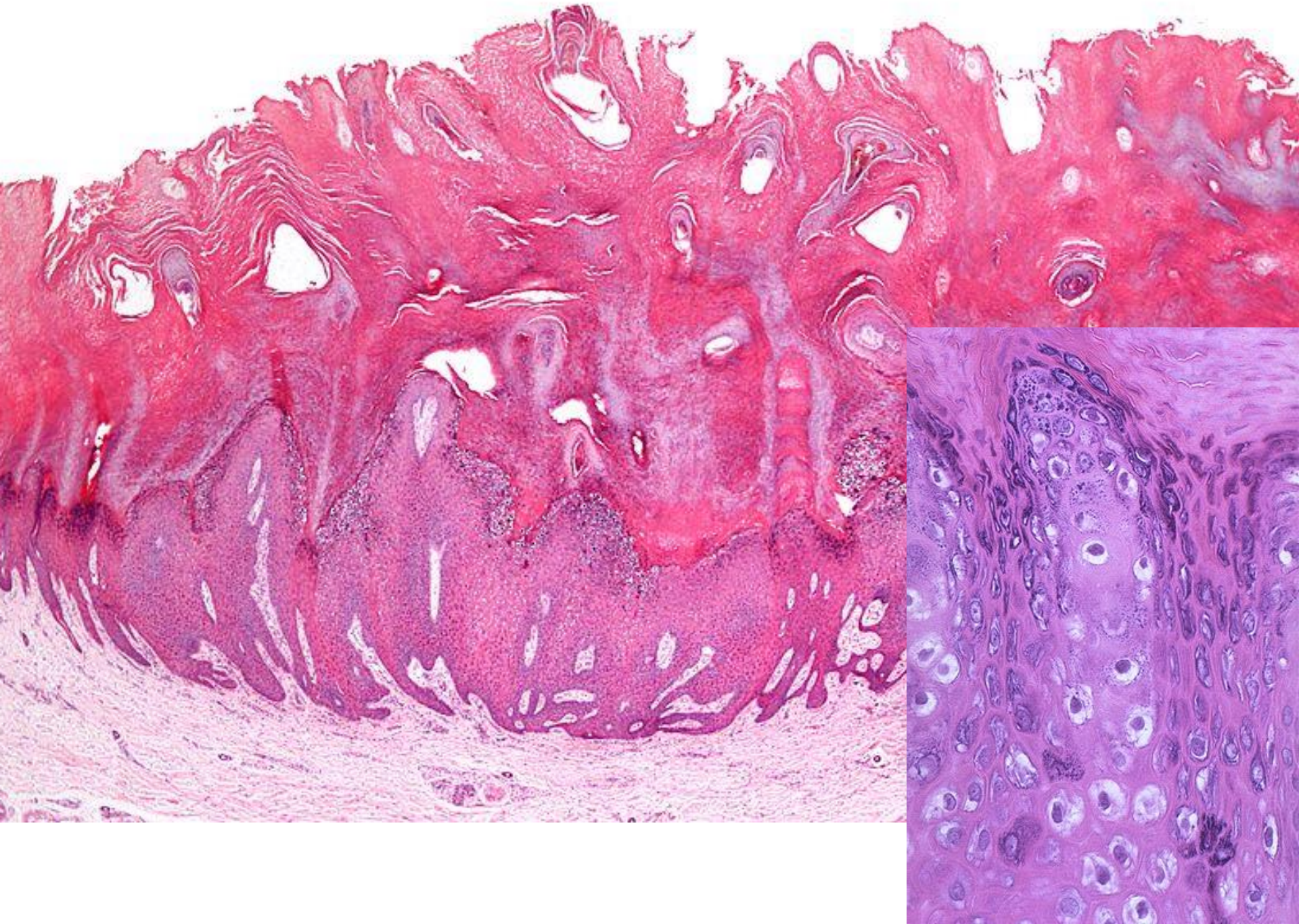

Epidermal nevus

- Benign congenital epidermal lesion resembling a papillomatous/hyperkeratotic SebK
- Localized, multiple unilateral in linear pattern, diffuse
- May be sporadic, syndromic or part of Nevus sebaceus (apocrine glands, sebaceous hyperplasia, adnexal neoplasms)

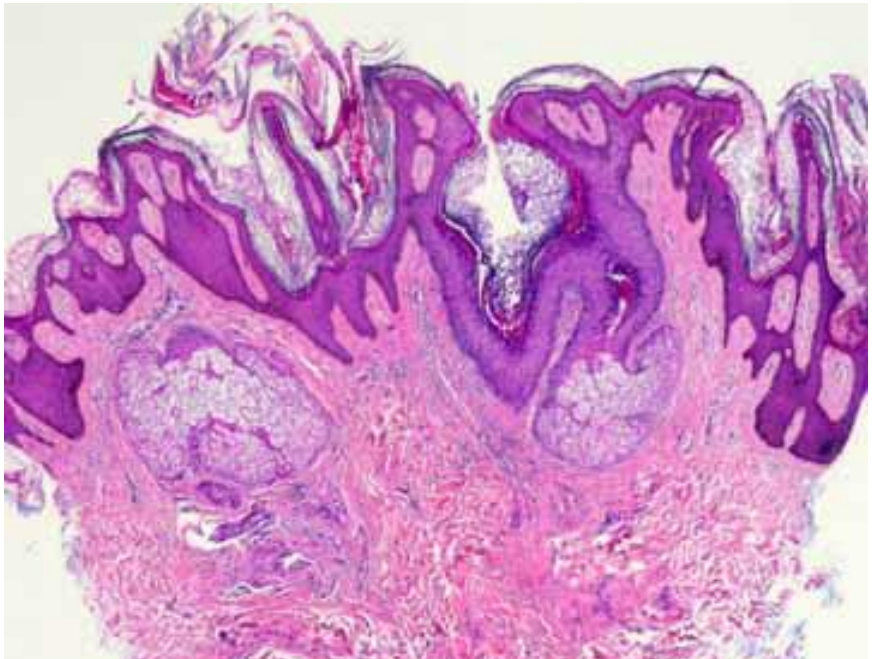

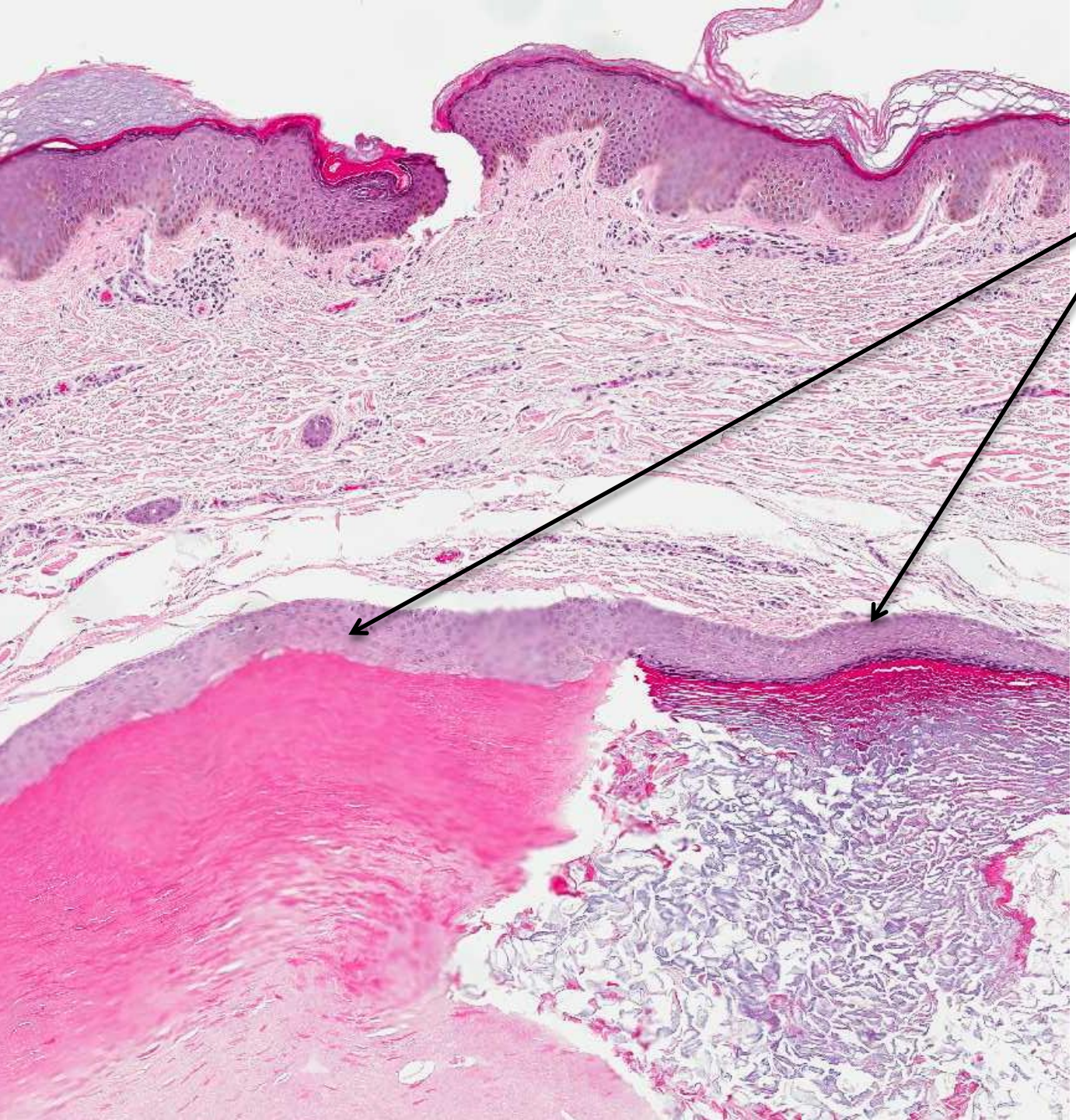

<u>Hybrid cyst</u>:

- Part **Pilar cyst**: Compact tricholemmal type keratinization; absence of granular cell layer

- Part **Epidermoid cyst**: Flaky epidermal type keratinization; presence of granular cell layer

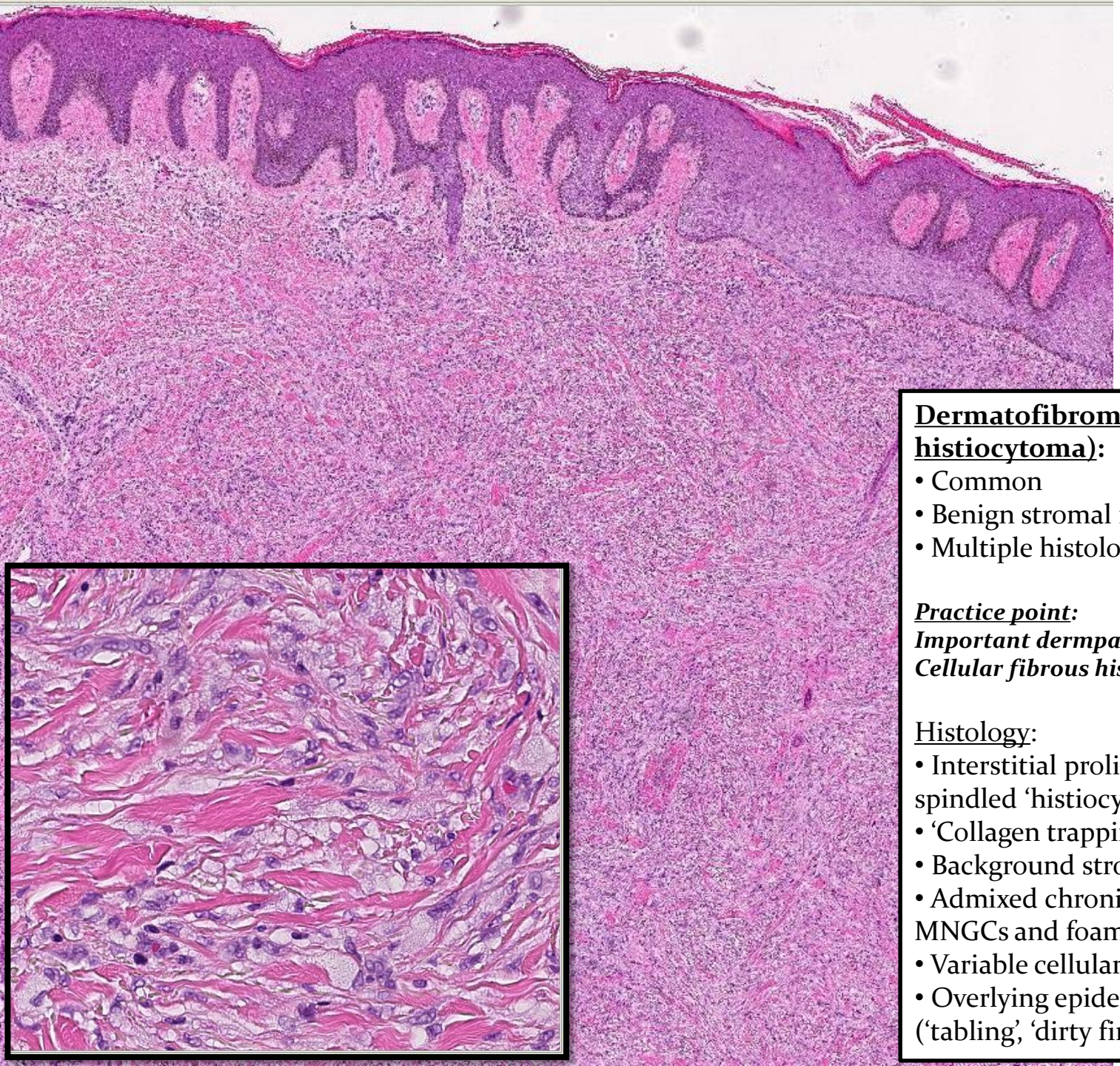

<u>Dermatofibroma (Benign fibrous histiocytoma)</u>:

- Common
- Benign stromal fibrohistiocytic lesion
- Multiple histological subtypes

<u>Practice point</u>:
Important dermpath DDx:
Cellular fibrous histiocytoma vs DFSP

<u>Histology</u>:

- Interstitial proliferation of stellate to spindled 'histiocytoid' stromal cells
- 'Collagen trapping' at edges
- Background stroma is fibrotic
- Admixed chronic inflammation (often MNGCs and foamy histiocytes)
- Variable cellularity
- Overlying epidermal induction ('tabling', 'dirty fingers')

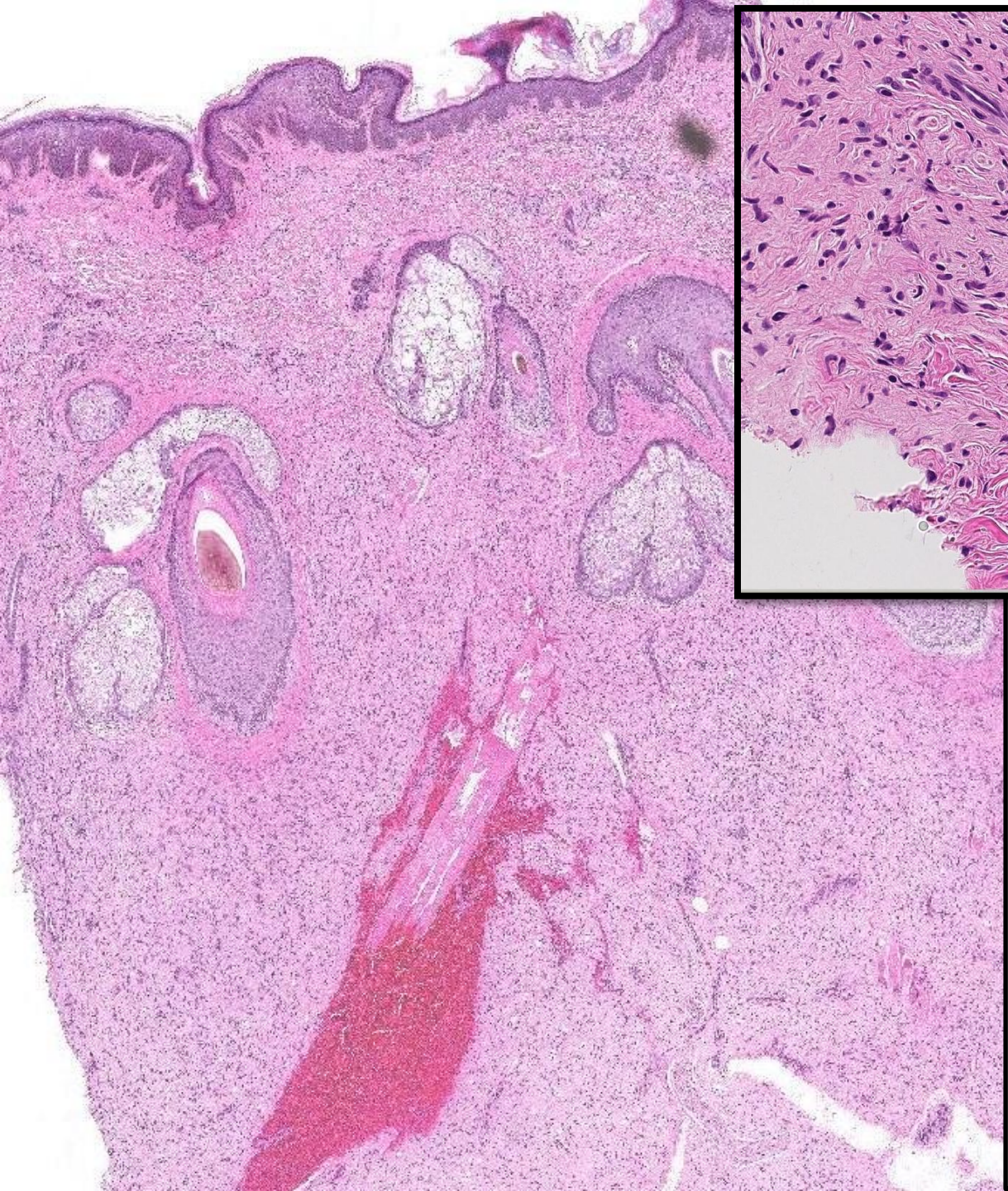

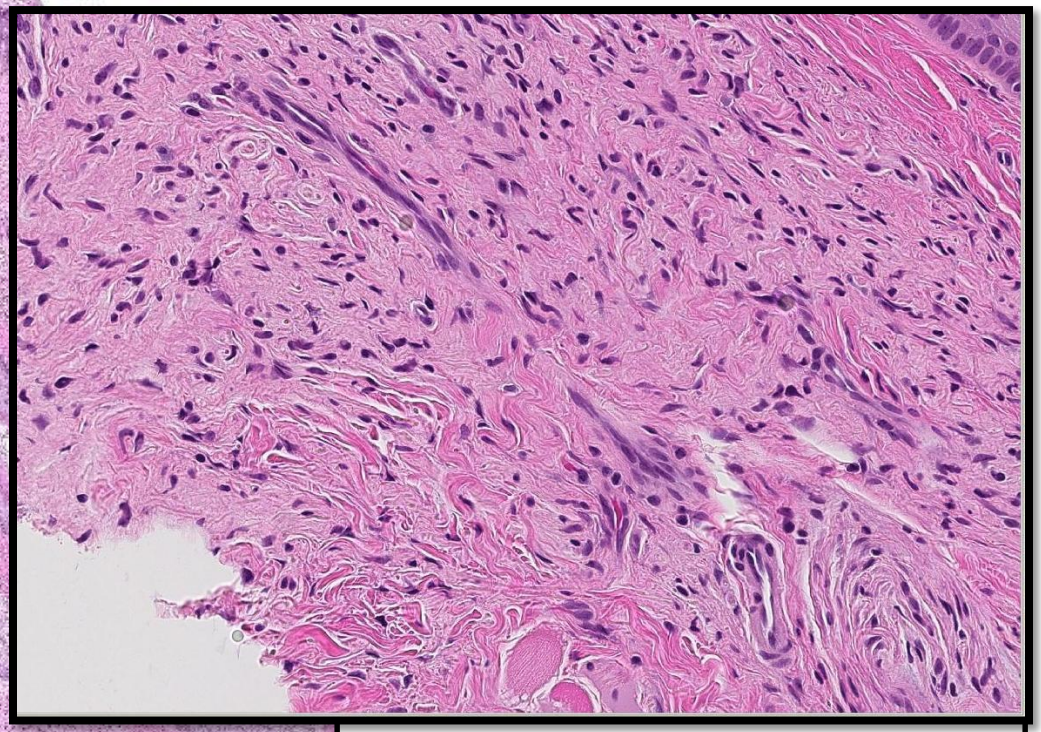

<u>Neurofibroma</u>:

- Common
- Benign stromal neural lesion

<u>Practice point</u>:
Typically sporadic lesions
Diffuse and Plexiform subtypes – think Neurofibromatosis Type I

<u>Histology</u>:

- Proliferation of small slender and wavy spindle cells
- Myxoid background (mucin)
- Admixed mast cells
- Fine collagen fibres in background ("shredded carrots")

Case 2

- 19 yr M
- L forearm
- “Tumour”
- Excision

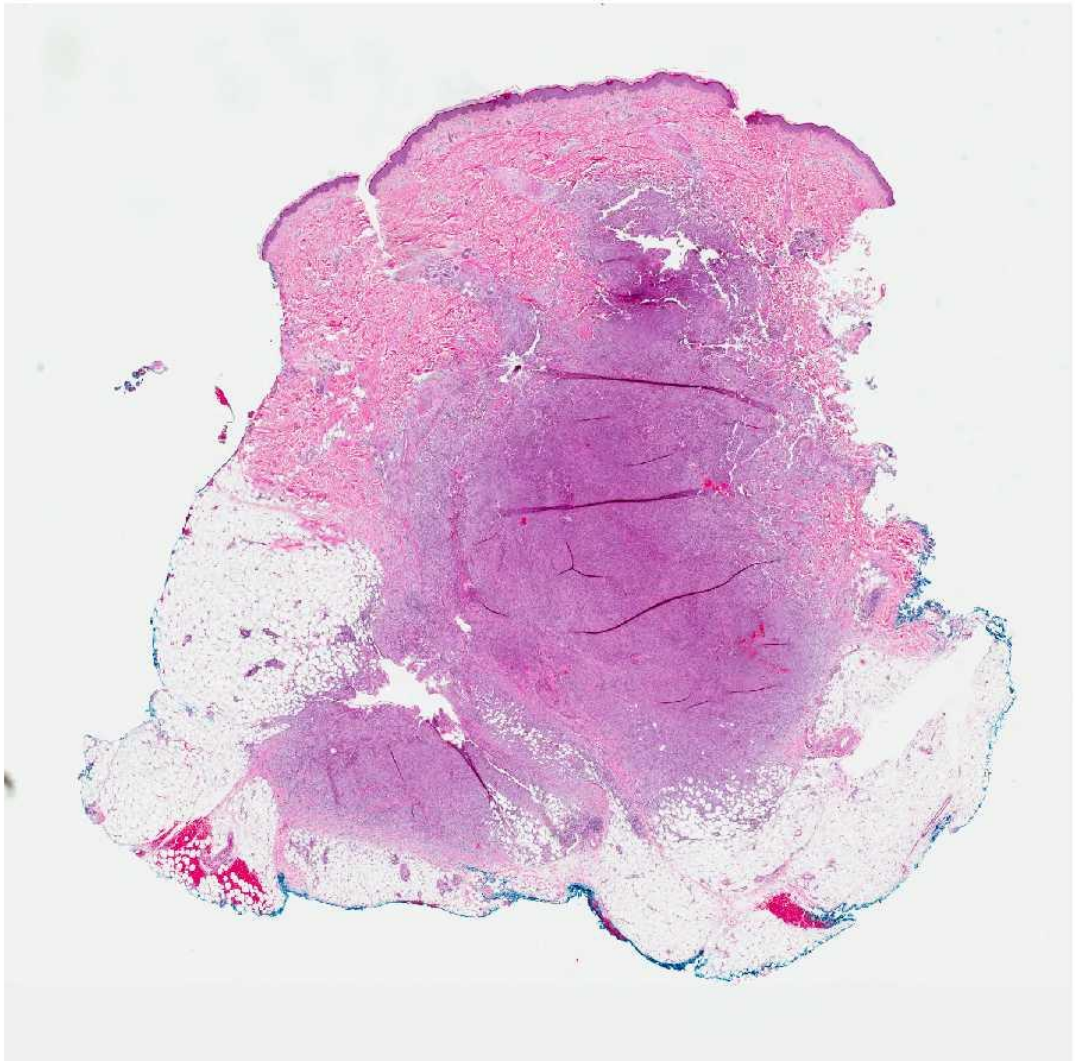

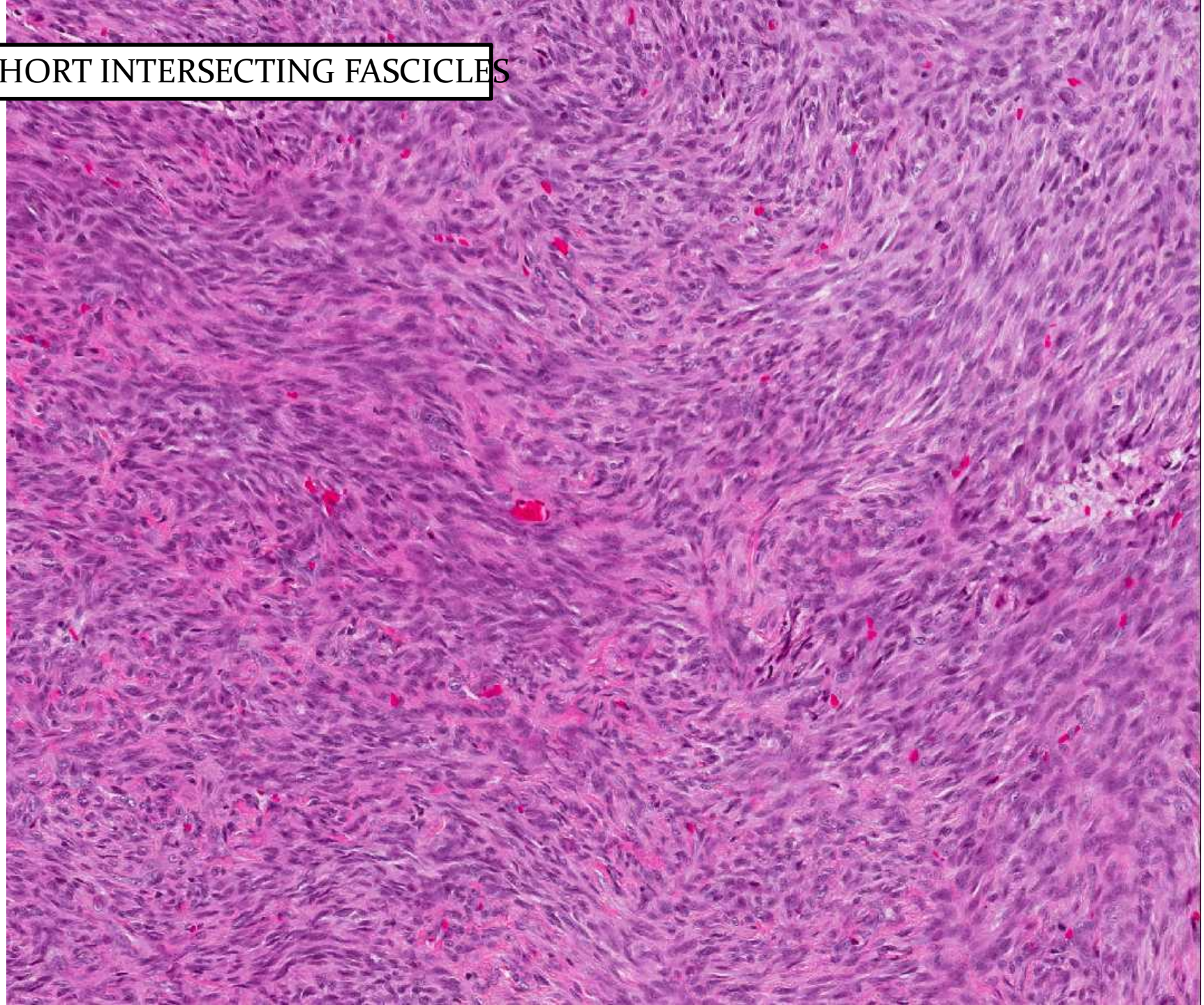
SHORT INTERSECTING FASCICLES

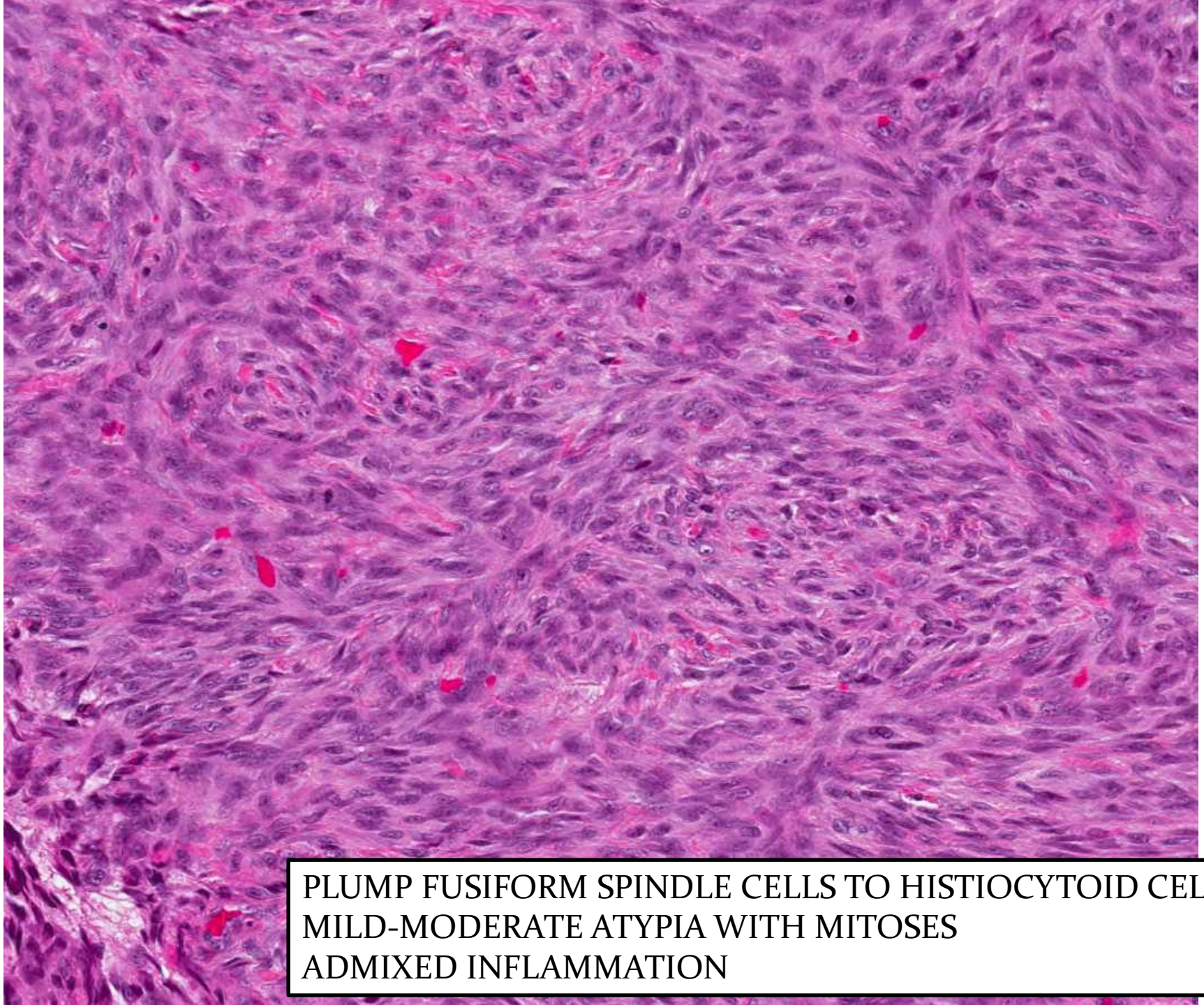
PLUMP FUSIFORM SPINDLE CELLS TO HISTIOCYTOID CELLS
MILD-MODERATE ATYPIA WITH MITOSES
ADMIXED INFLAMMATION

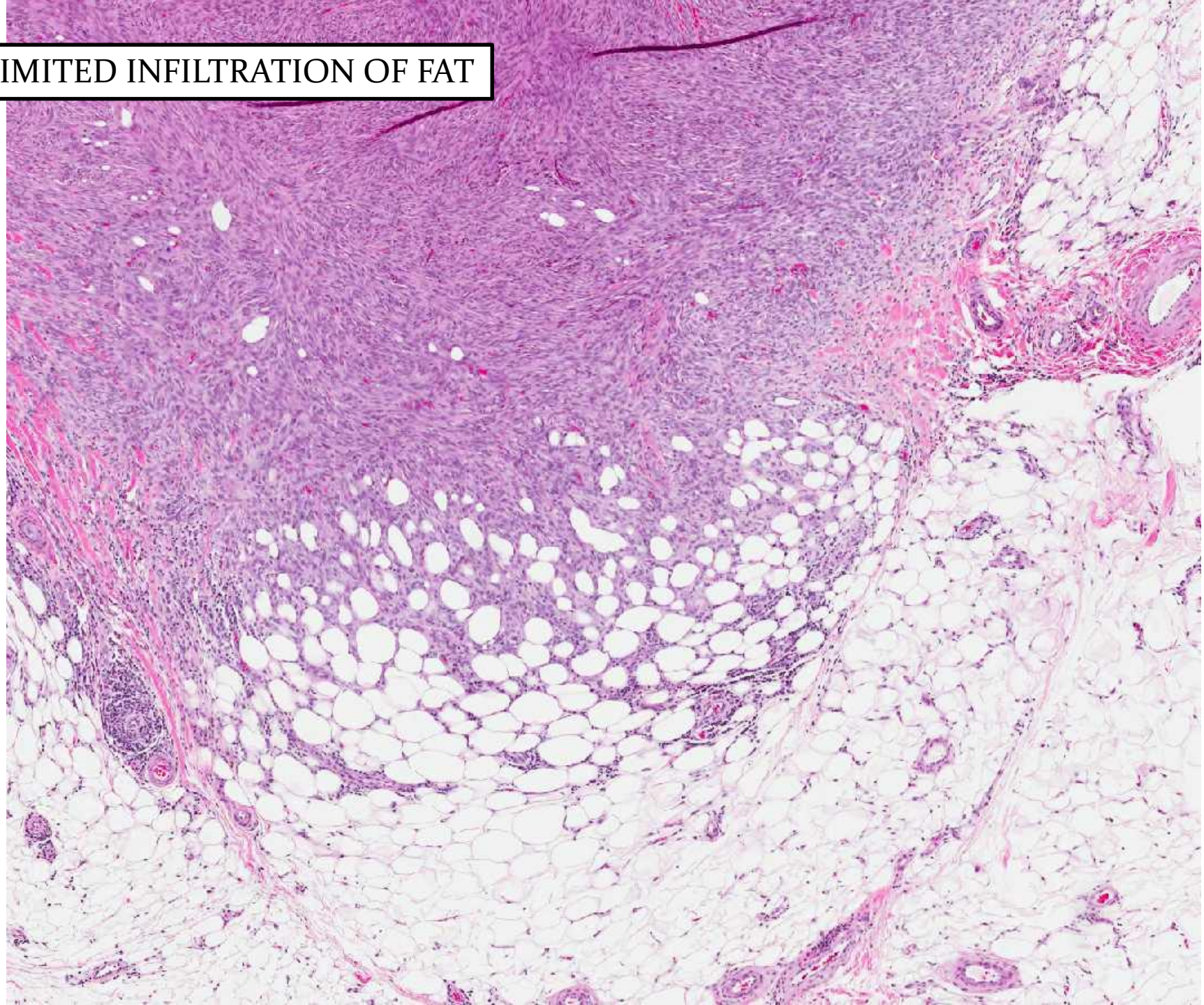
LIMITED INFILTRATION OF FAT

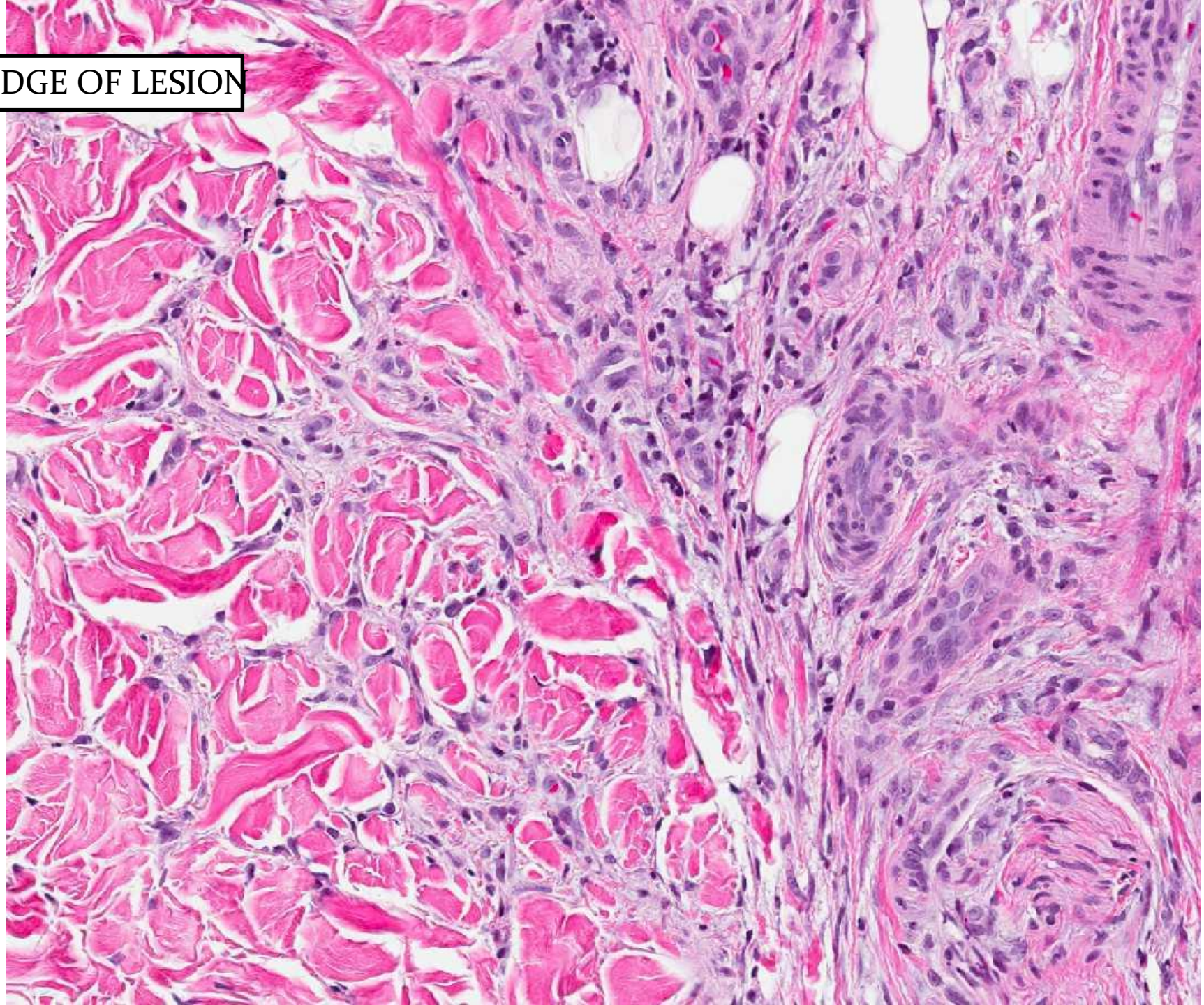
EDGE OF LESION

CD34

FACTOR XIIIA

CELLULAR FIBROUS HISTIOCYTOMA

- Variant of Benign fibrous histiocytoma
- Similar clinical presentation – dermal nodule
- Defined by hypercellularity and often deeper location in dermis +/- subcutis and often larger size (but usually 1-2cm)
- Cells typically more pronounced spindle cells with atypia and mitotic activity
- May show necrosis
- Risk of recurrence with incomplete excision
- Complete excision recommended

Diagnostic challenges vs DFSP

- May involve fat but different pattern
- May show patchy CD34 positivity
- May have storiform pattern

- Clues:
  - Background BFH
  - Epidermal induction
  - Admixed inflammatory cells
  - ***Different cytology and architecture***
  - ***Immunohistochemistry (CD34, Factor XIIIa)***
  - ***Clinical: CFH = deep-seated (?cyst, nodule, DF)***
    DFSP = plaque / tumour (?keloid, tumour)

Dermatofibrosarcoma protuberans

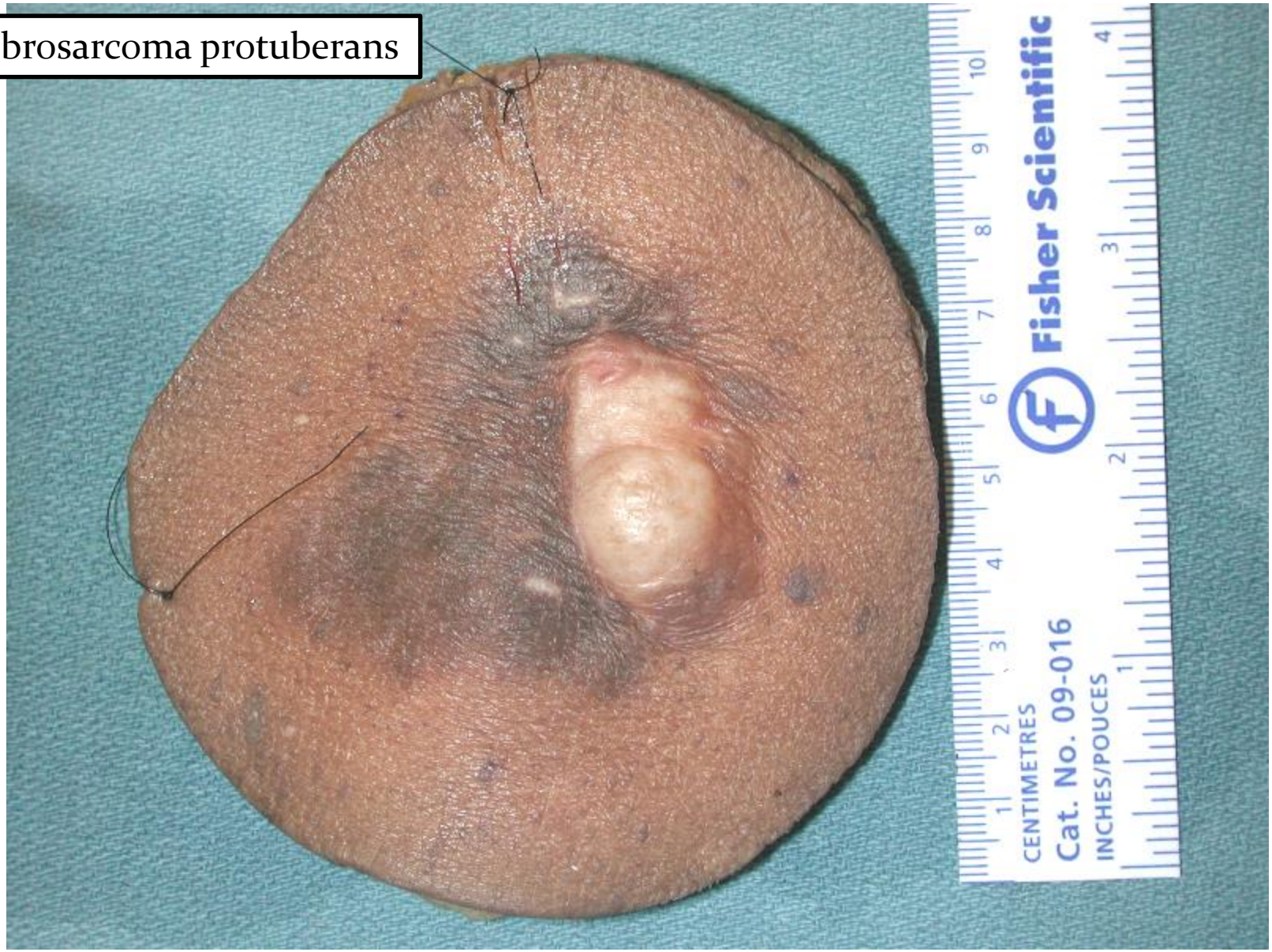

Dermatofibrosarcoma protuberans

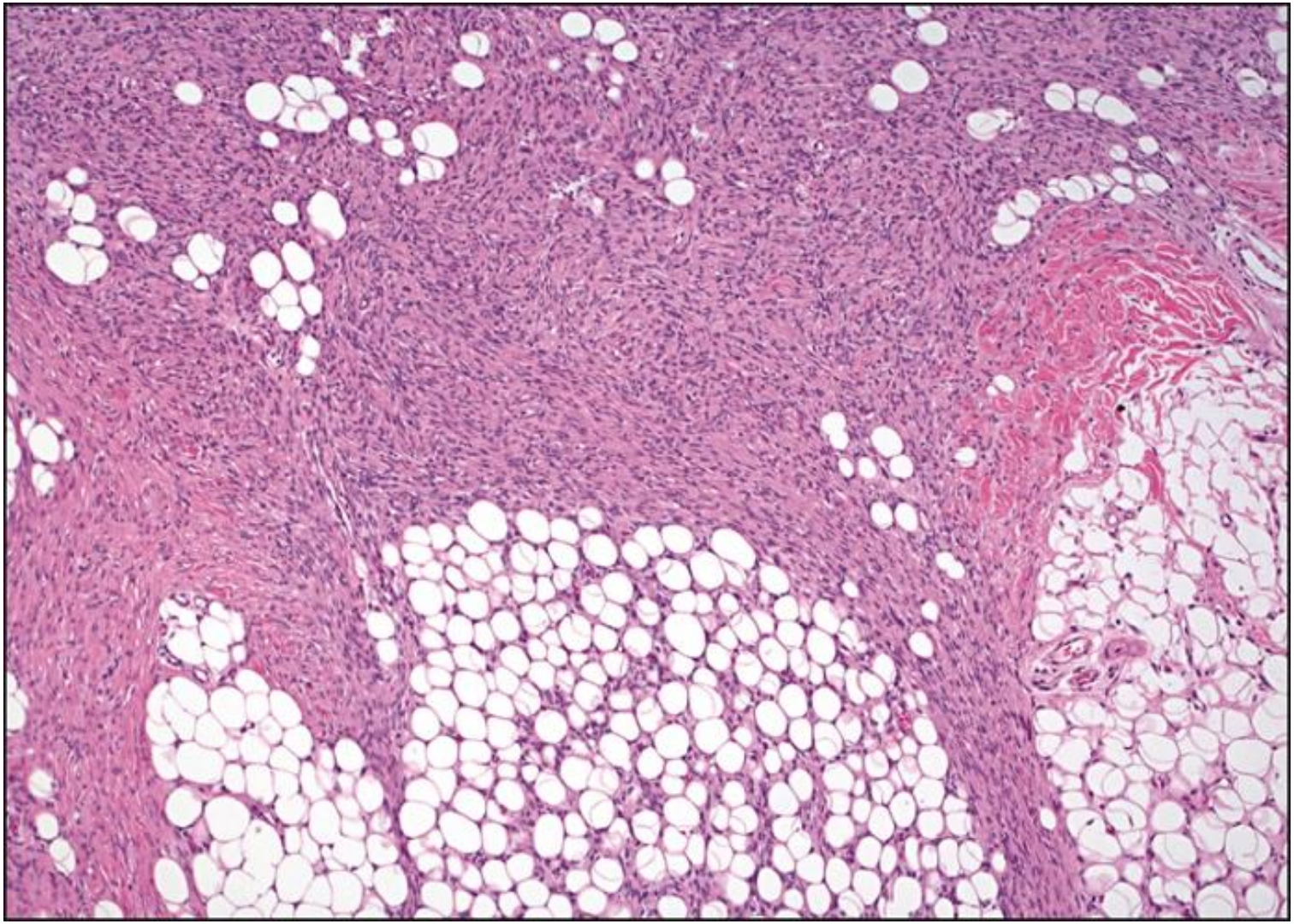

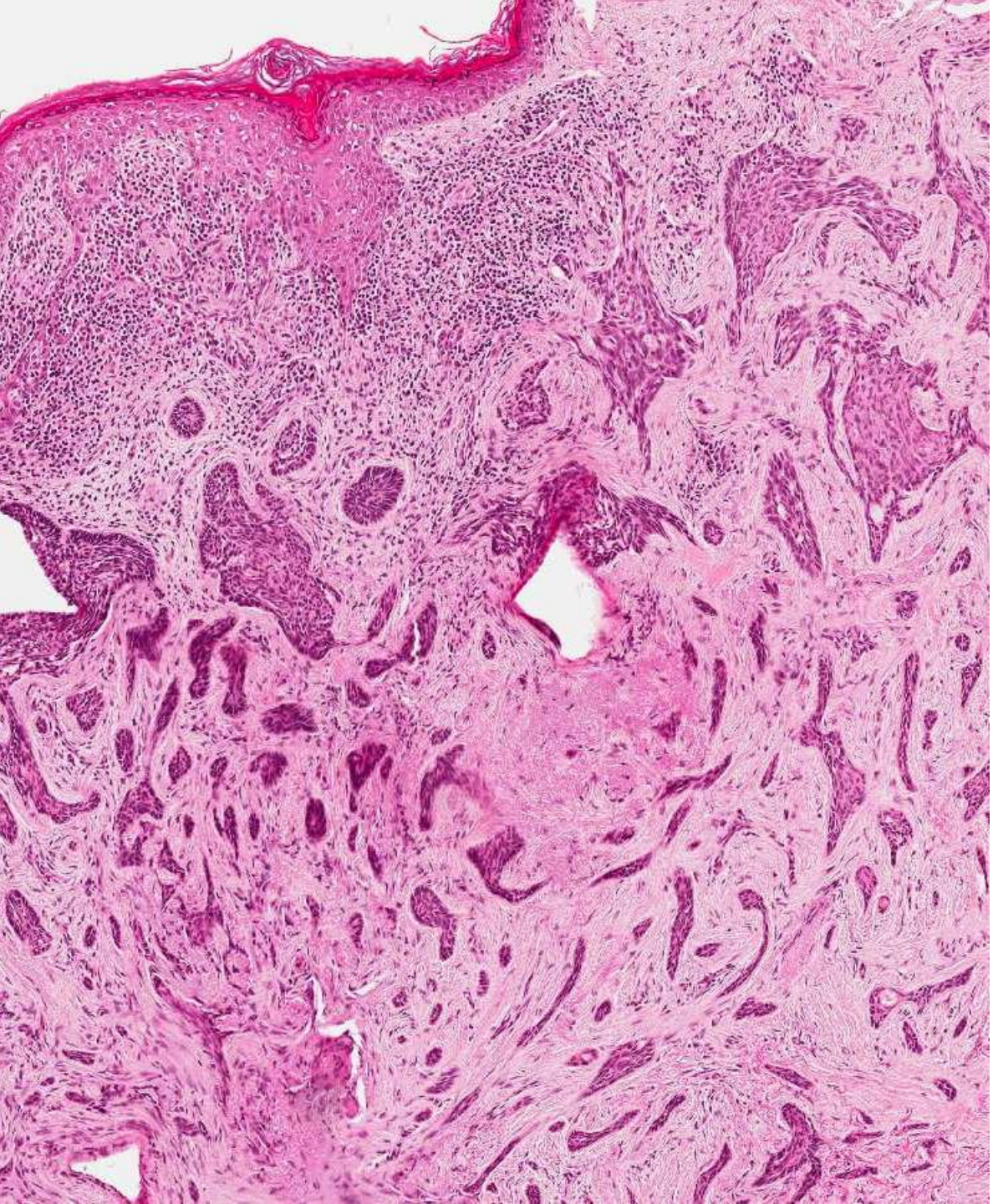

<u>Basal cell carcinoma</u>:

- Common
- Malignant epidermal lesion
- Multiple histological subtypes

<u>Practice point</u>:
Know the important subtypes: Sclerosing, Infiltrative, Micronodular, Metatypical/Basosquamous, Superficial

<u>Histology</u>: - depends on subtype

- Proliferation of infiltrating and destructive basaloid islands
- Stromal retraction, Peripheral palisading .. may be subtle or absent in some subtypes
- Atypia, Apoptoses, Mitoses, Necrosis

Case 8

Clinical info:

50 yr F, forehead

Excision

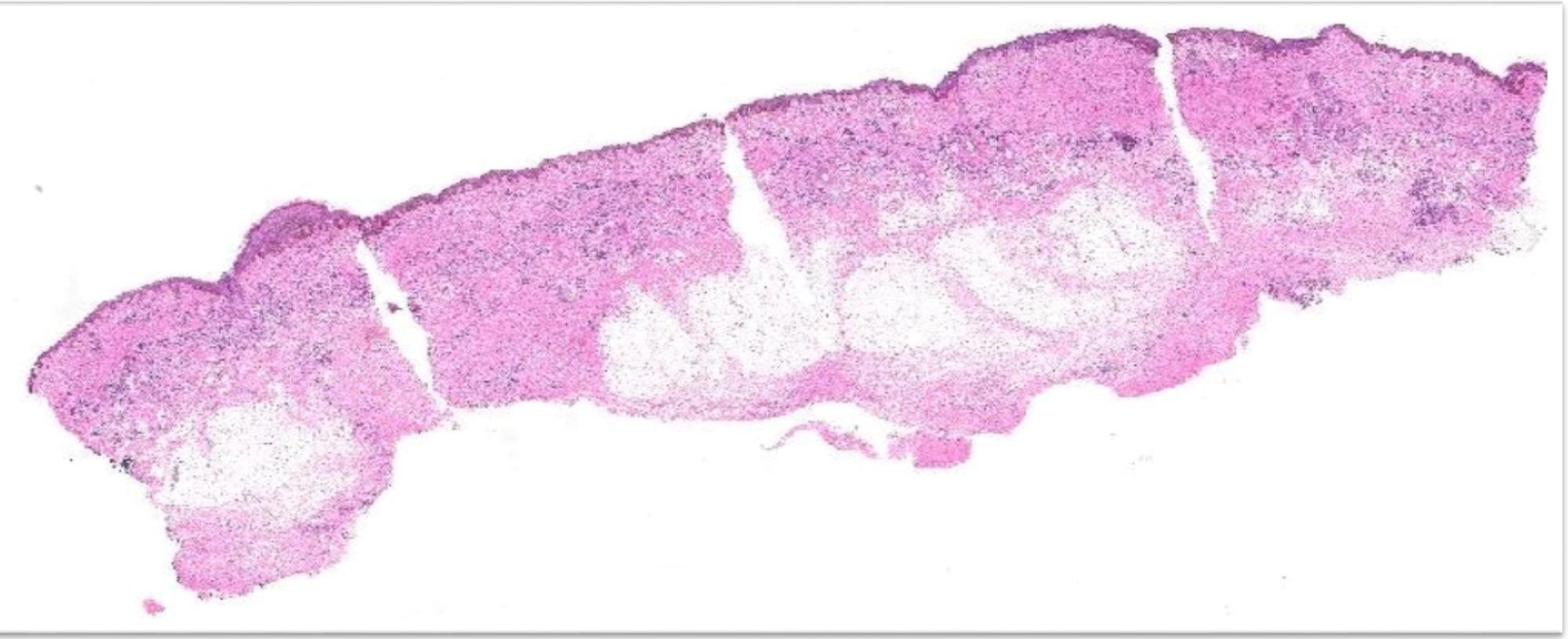

Dermal proliferation:
- small infiltrative basaloid islands
- some associated myxoid stroma
- glandular? pseudoglandular?
- epidermis unremarkable
- background scar

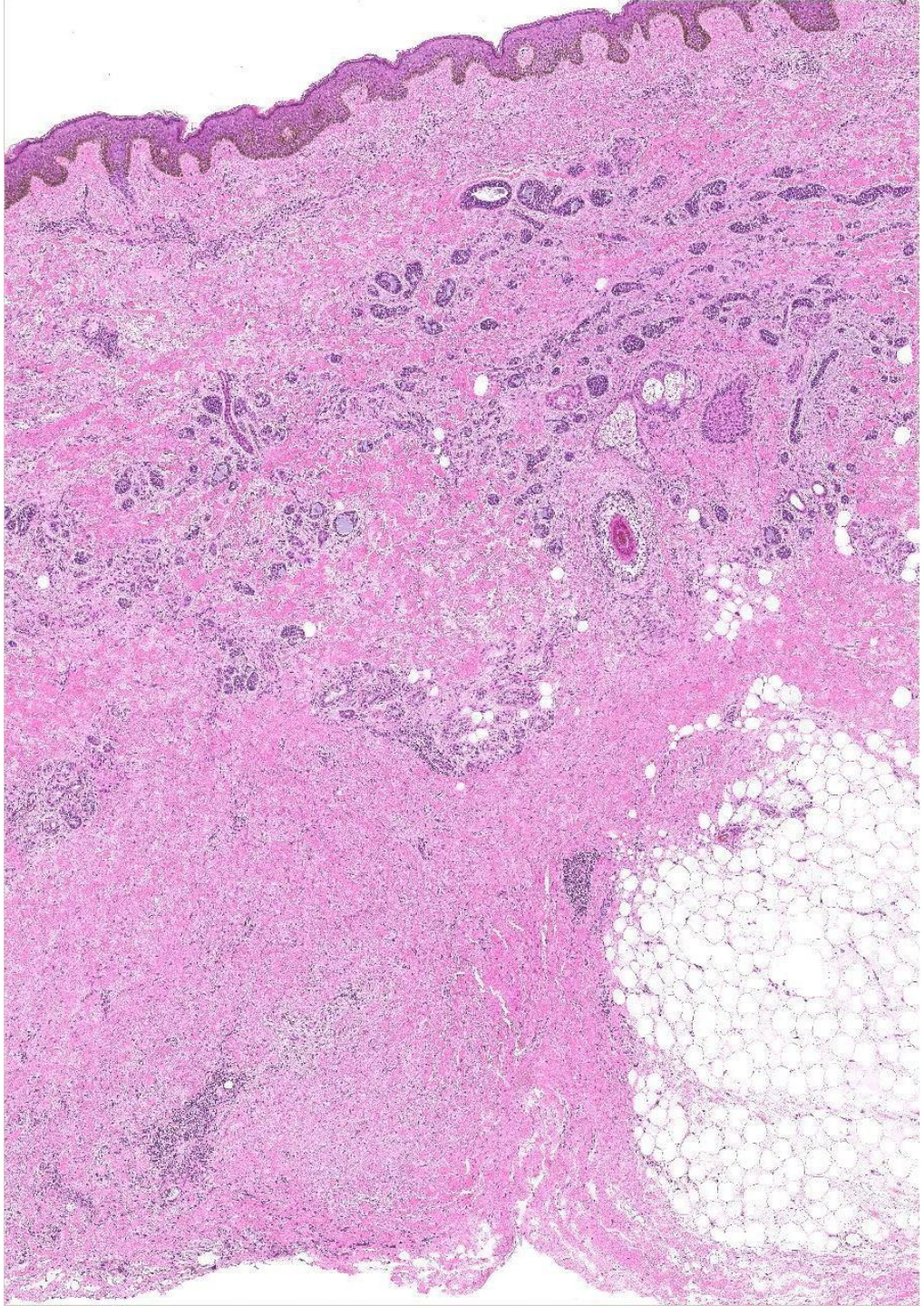

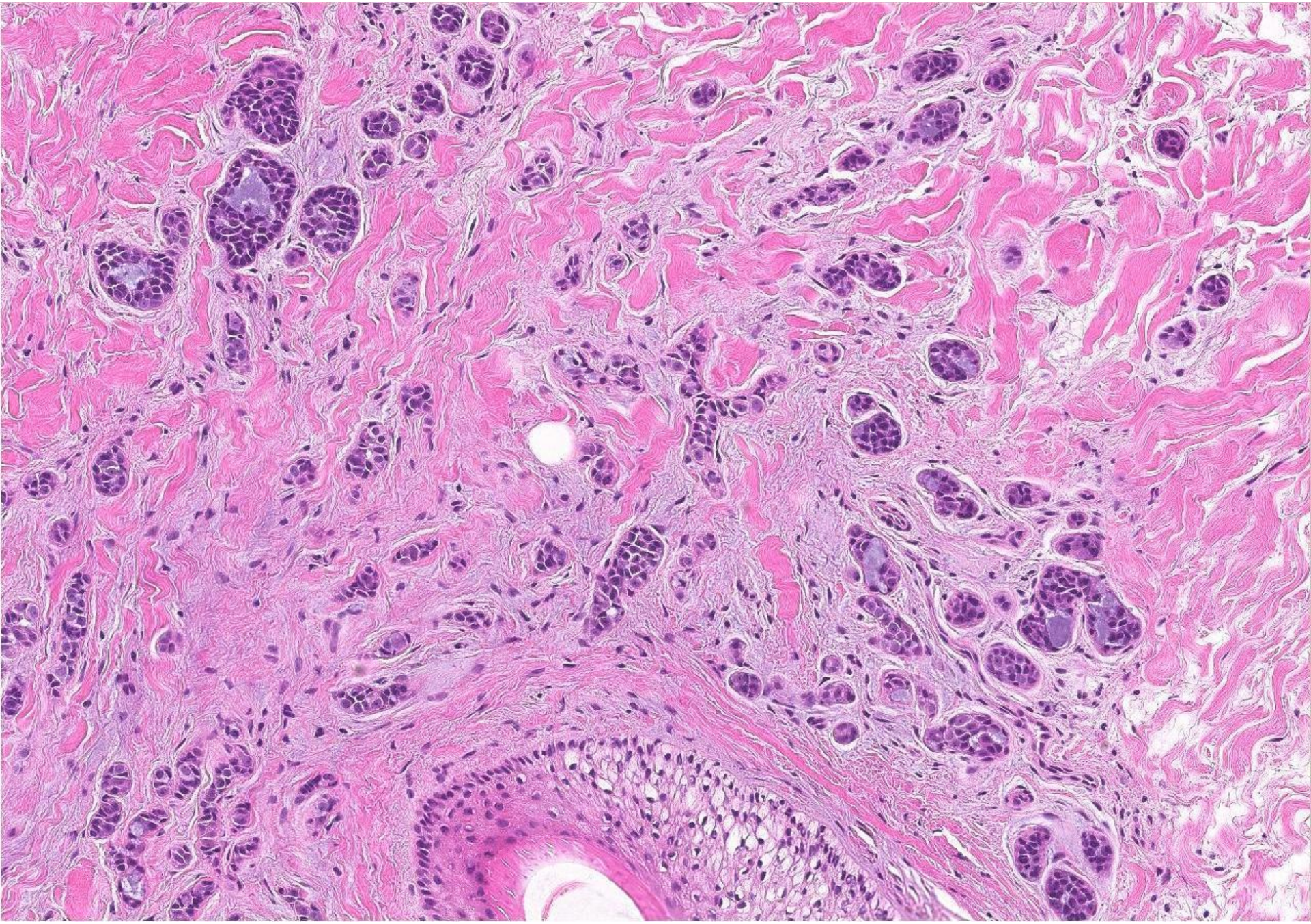

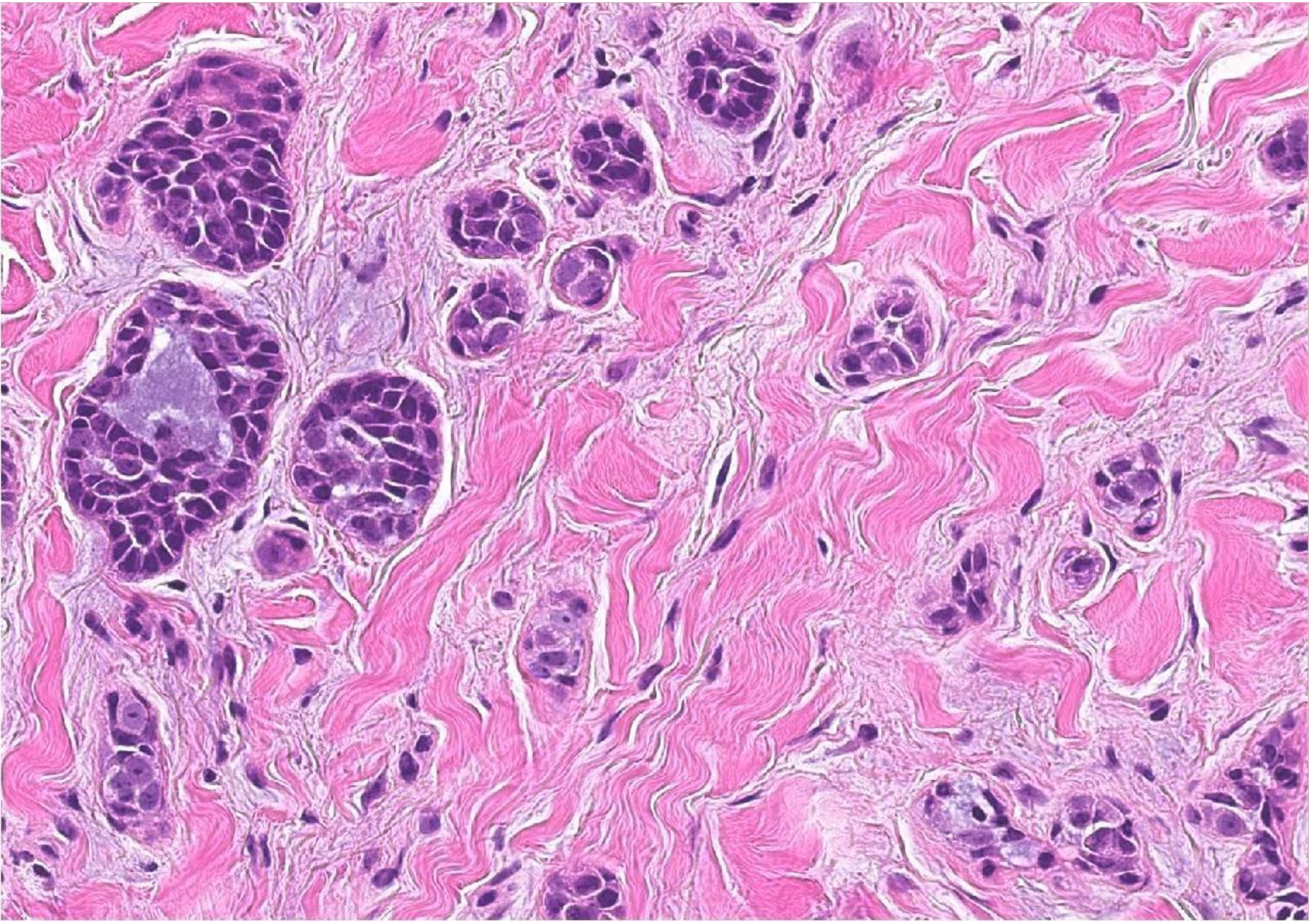

Diagnosis

- Basal cell carcinoma, micronodular type

Basal cell carcinoma

Relevant histologic subtypes:

- Superficial
- Micronodular
- Infiltrative
- Sclerosing / Morpheaform
- Metatypical / Basosquamous

Subtypes with no clinical relevance:

- Nodular / Solid
- Infundibulocystic
  - *vs Trichoepithelioma*
- Keratotic
- Pigmented
- Cystic / Adenoid
- Fibroepithelioma of Pinkus
- Clear cell
  - *vs Trichilemmoma / other clear cell tumours*
- Granular cell, Pleomorphic
- Metaplastic:
  - BCC with sebaceous differentiation
  - BCC with eccrine differentiation
    - *vs Microcystic adnexal carcinoma (MAC)*
  - BCC with chondroid / osseous metaplasia

Basal cell carcinoma - subtypes

SuperficialBCC

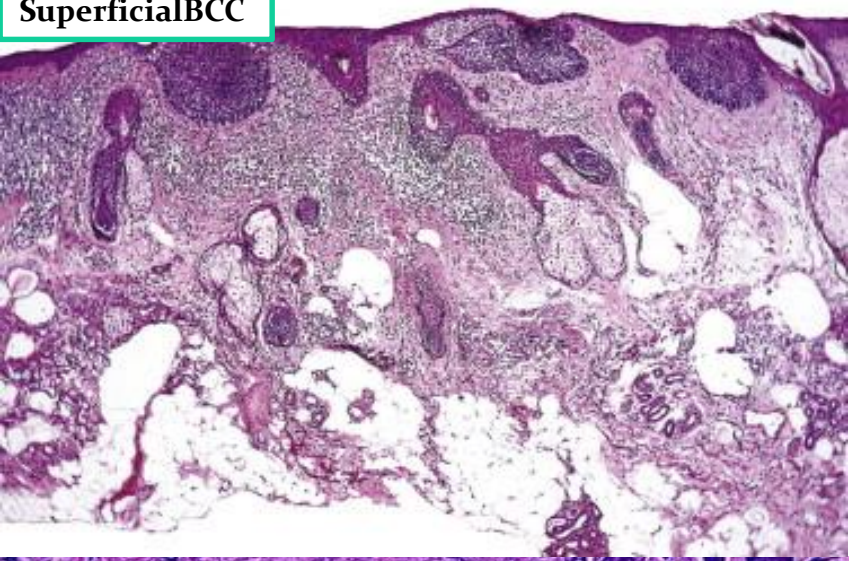

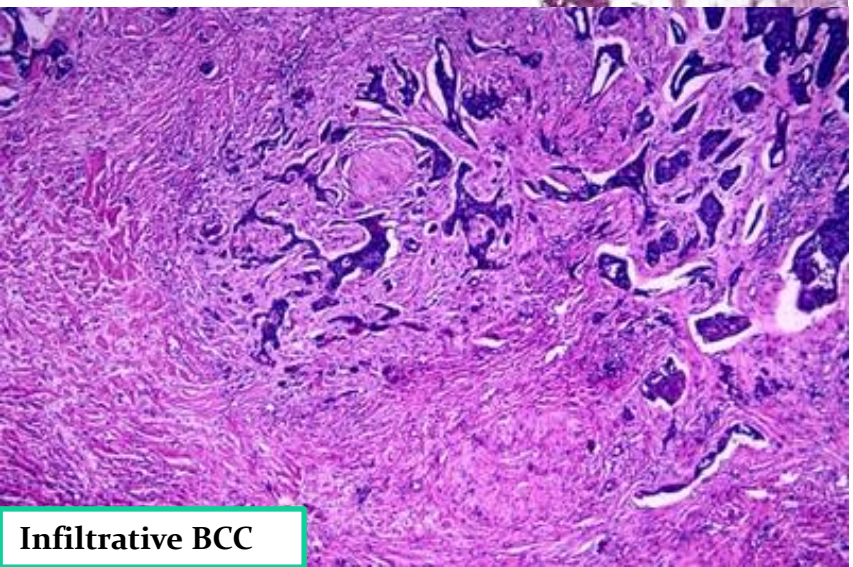

Infiltrative BCC

MicronodularBCC

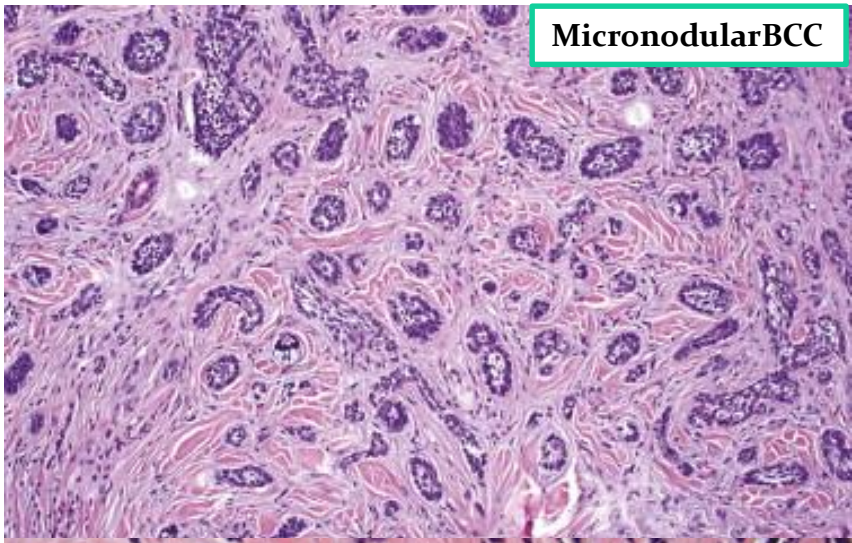

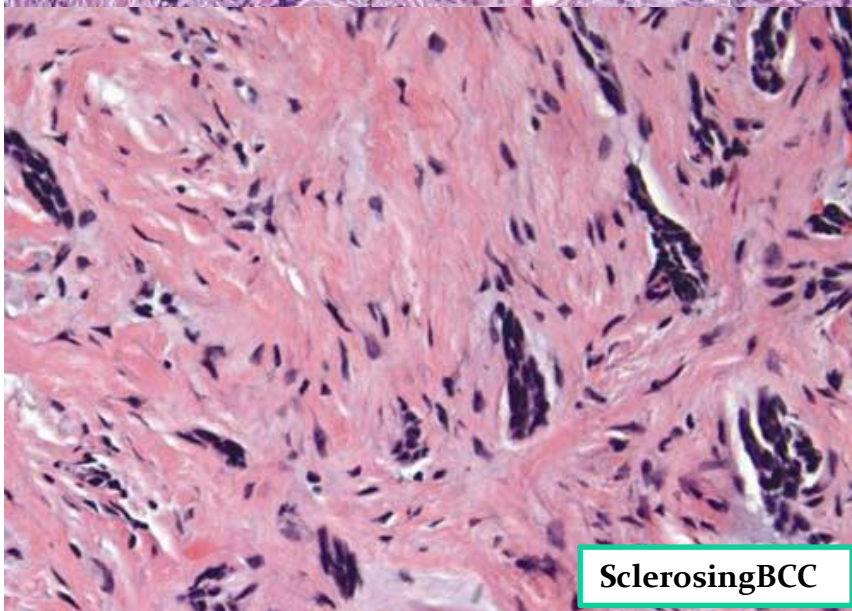

SclerosingBCC

Basal cell carcinoma

Subtypes

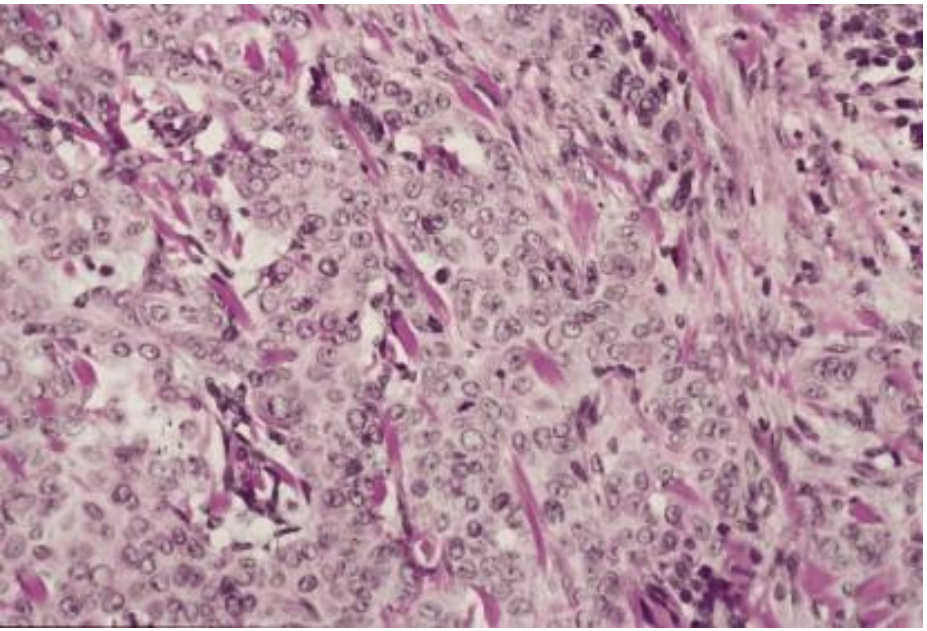

Metatypical BCC

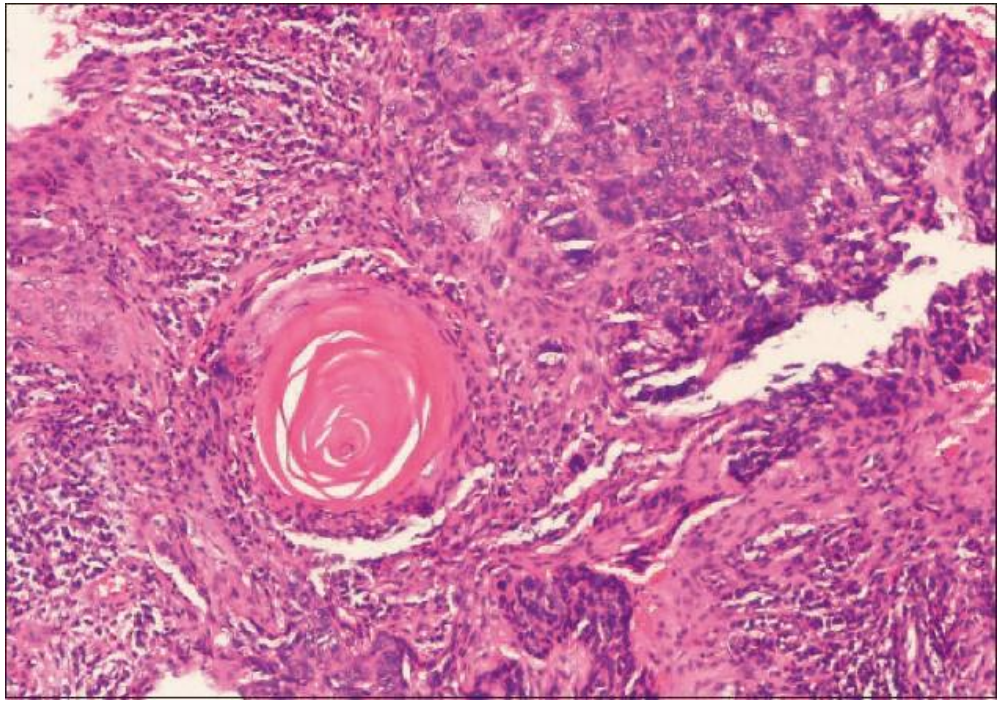

Basosquamous carcinoma

Other important skin neoplasms:

Malignant:

- Melanoma
  - Lentigo maligna
  - Desmoplastic melanoma
- Merkel cell carcinoma
- Atypical fibroxanthoma (AFX)
- Kaposi sarcoma
- Angiosarcoma
- Dermatofibrosarcoma protuberans (DFSP)
- Mycosis fungoides
- Other CTCLs
- Microcystic adnexal carcinoma (MAC)
- Extramammary Paget's disease

Benign:

- Dysplastic nevi
- Spitz nevi
- Blue nevi
- Cellular fibrous histiocytoma
- Benign adnexal tumours
- Cellular neurothekeoma
- Schwannoma
- Leiomyoma
- Pseudolymphoma

Challenges in dermatopathology:

Important pitfalls

- Melanoma
  - Nevoid melanoma vs Benign nevus
  - Melanoma vs Spitz nevus
  - SSM vs Dysplastic nevus
  - Nevi of special sites
  - Irritated or Recurrent nevi
  - Halo nevi
  - Intranodal nevi vs Metastatic melanoma
- Reactive atypia vs dysplasia
- Pseudoepitheliomatous hyperplasia vs SqCC
- Irritated SK / Inverted follicular keratosis
- Cellular fibrous histiocytoma vs DFSP
- Microcystic adnexal carcinoma vs Syringoma
- Desmoplastic trichoepithelioma vs carcinoma
- Sebaceous carcinoma vs BCC / other basaloid tumours
- Atypia / mitoses in Pilomatrixoma
- Epithelioid sarcoma vs Palisaded granuloma
- Low-grade B-cell lymphomas vs Pseudolymphoma
- …. many others

Diagnoses that can be easy to miss

- Lentigo maligna
- Desmoplastic melanoma
- Kaposi sarcoma
- Mycosis fungoides
- Metastatic carcinoma (breast)
- Atypical vacular lesion / Well-differentiated Angiosarcoma
- Mastocytosis
- Granular cell tumour
- Granuloma annulare
- Dermatofibroma
- Superficial fungal infection
- Urticaria
- Porokeratosis
- Amyloidosis
- Pigmented purpura
- Secondary syphilis
- Grover's disease
- …. many others

Other challenges:

- Many other rarer tumours not mentioned so far
- Reactive pseudo-tumoural processes
- Tumour variants
- Tumours with imperfect diagnostic features
- Suboptimal / insufficient biopsies, Inappropriate biopsy requests, etc.

…. complexity can become intimidating!

Strategy:

- Know the common conditions.
- Know the important conditions.
- Know the important 'pitfalls'
- Know when you are out of your comfort zone, proceed with caution and seek help!

- Continually build upon this foundation of knowledge.

Hint: Lesions with characteristic / pathognomonic histological features also make great cases for rapid diagnosis testing (e.g. Pilomatrixoma; Mixed tumour of skin; Sclerotic fibroma; Schwannoma; Pemphigus vulgaris; Dermatitis herpetiformis; Herpes simplex; Molluscum contagiosum; Cutaneous leishmaniasis, etc.)

2 - Melanocytic lesions

Lentigo (simple, solar)

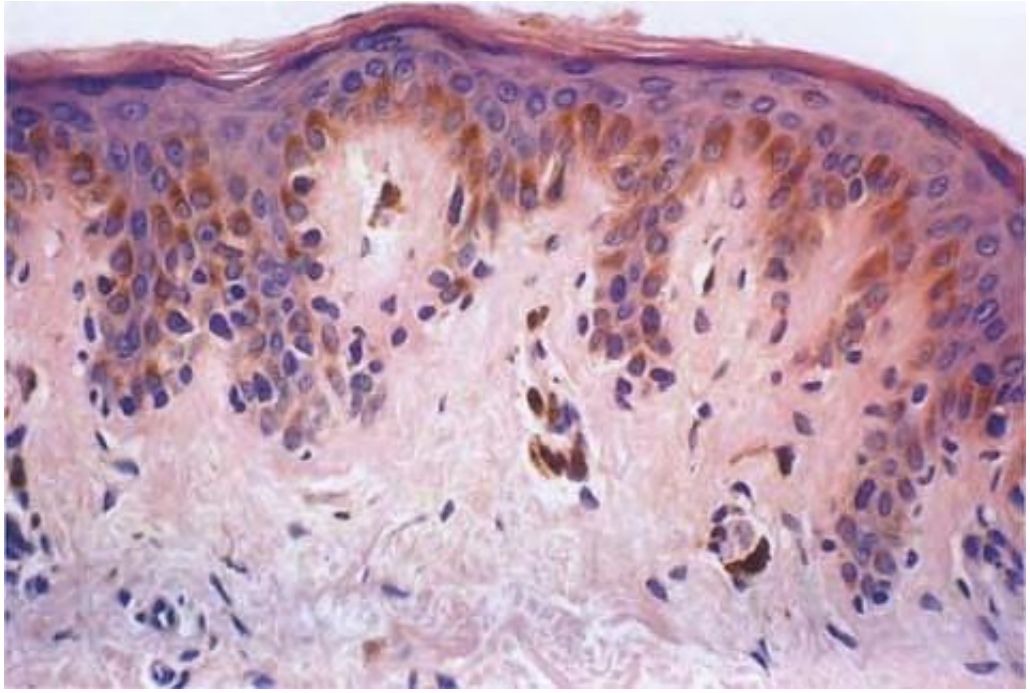

Benign melanocytic nevus

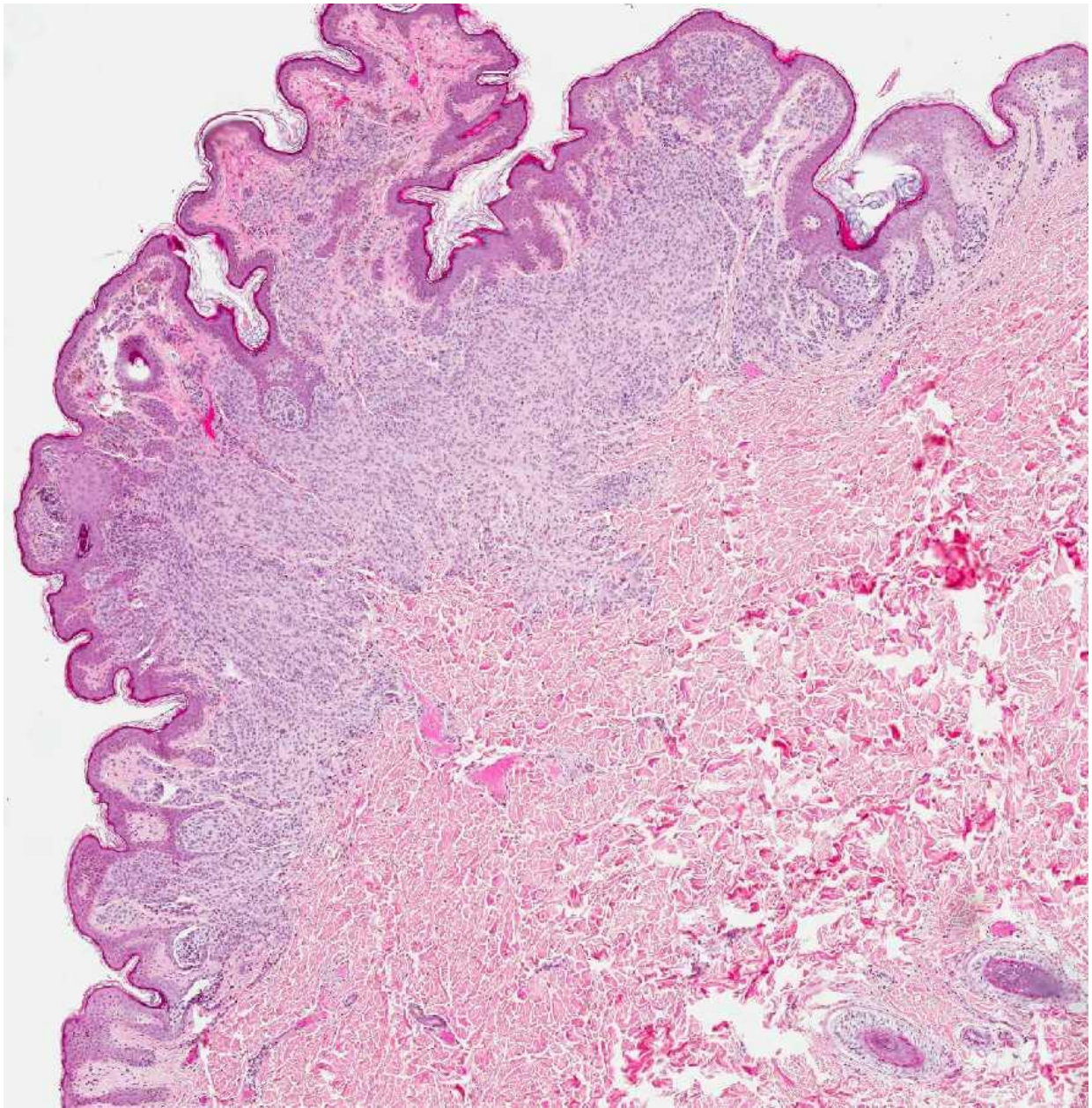

Architecture:
- Often small (unless congenital)
- Symmetrical
- Well-circumscribed
- Maturation (nested → diffuse)

Cytology:
- Cells are small
- Small to absent nucleoli
- No cytologic atypia
- No mitotic activity
- Cytologic maturation (decrease in size, loss of nucleoli, diminished cytoplasm, loss of pigmentation, may take on spindled morphology)

Atypical findings:
- Confluent or expansile growth
- Pagetoid spread
- Epidermal consumption / ulceration
- Dermal mitotic activity
- Cytologic atypia

Note: Don't overcall benign nevi with reactive changes which may show some 'pseudomelanomatous' features

Melanoma - diagnosis

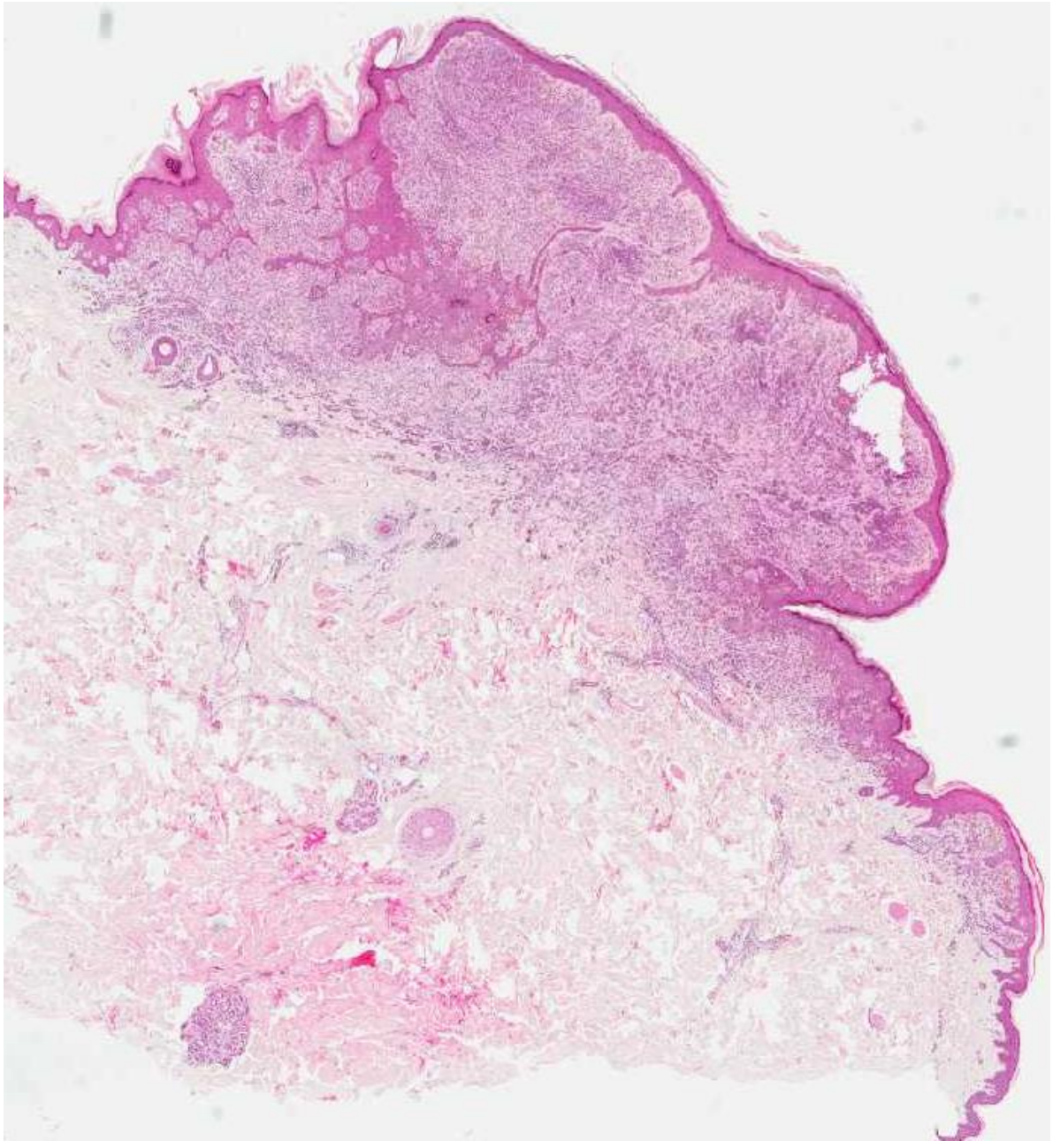

Architecture:
Can be quite variable but ….
- Often large (may be small) and often growing or evolving
- Asymmetrical
- Variable circumscription
- Poor maturation

Cytology:
Can be quite variable but ….
- Cells generally enlarged
- Nucleoli (often macronucleoli)
- Cytologic atypia
- Dermal mitotic activity (may be absent) and may show increased Ki67 expression (i.e. > 10%)
- Poor cytologic maturation often incl. preserved dermal HMB45 expression

Atypical findings:
- Dense, confluent or expansile growth
- Pagetoid spread
- Epidermal consumption / ulceration
- Dermal mitotic activity
- Cytologic atypia

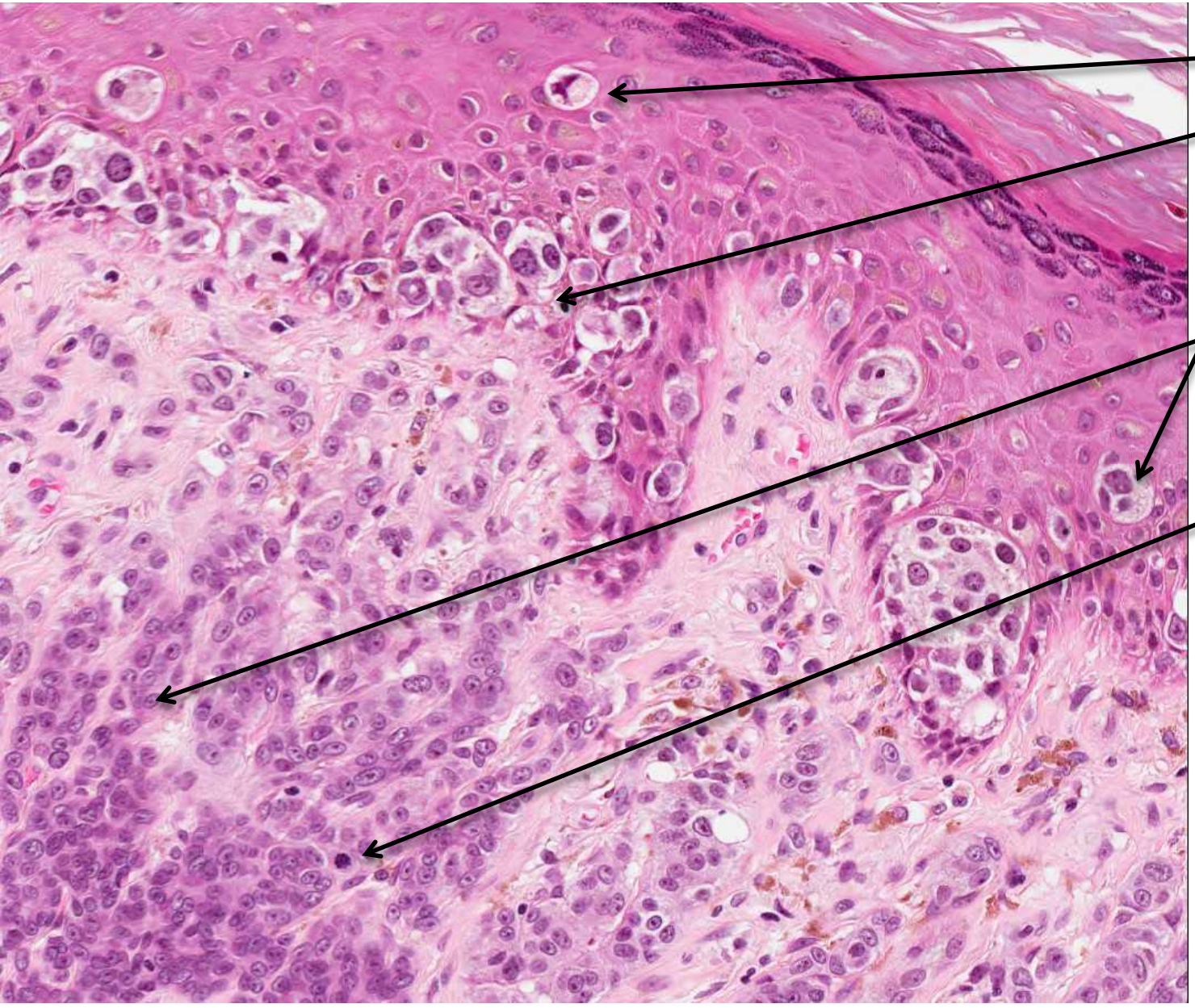
Pagetoid spread
Confluent junctional growth
Junctional cells are enlarged and atypical
But dermal cells are small and ‘nevoid’
Dermal mitoses

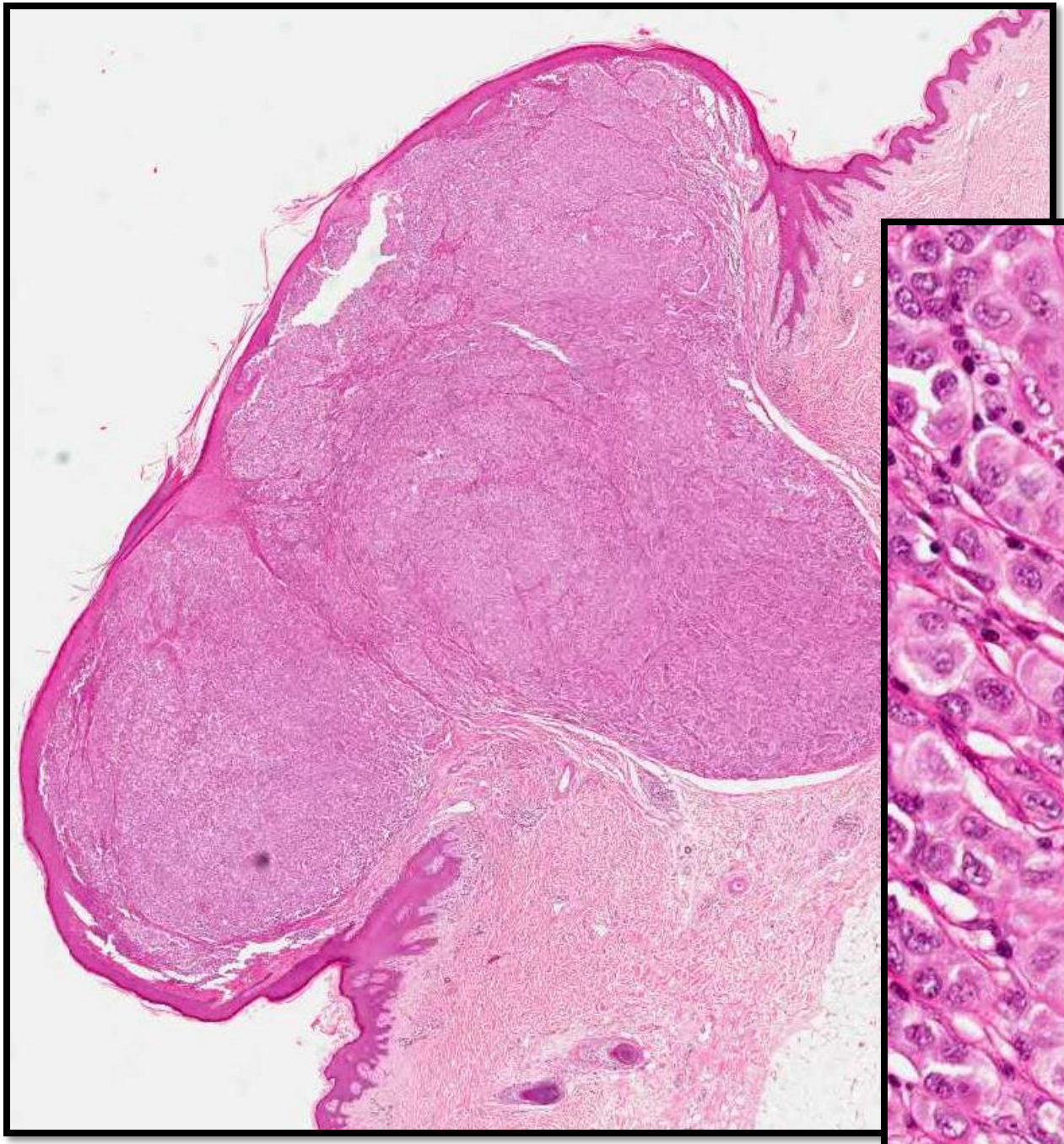

Melanoma Synoptic Reporting

Clinical documentation:

- Procedure
- Anatomic site, Laterality
- Solitary vs Multiple

Macroscopic features:

- Size
- Macrosatellites

Histological features:

- Histological subtype
- Breslow thickness
- Clark's level
- Ulceration
- Mitotic rate
- LVI
- PNI
- TILs
- Regression
- Microsatellites
- Growth phase (Radial, Vertical)
- Margin status (incl. measured distances)
- TNM staging incl. LN/distant met status if applicable

Other:

- Additional findings / diagnoses
- Commentary

References:

1. ***CAP protocols***
2. ***AJCC Handbook***

Melanoma Synoptic Reporting

Clinical documentation:

- Procedure
- Anatomic site, Laterality
- Solitary vs Multiple

Macroscopic features:

- Size
- Macrosatellites

Histological features:

- **Histological subtype**
- **Breslow thickness**
- Clark's level
- **Ulceration**
- **Mitotic rate**
- LVI
- PNI
- TILs
- **Regression**
- **Microsatellites**
- Growth phase (Radial, Vertical)
- Margin status (incl. measured distances)
- TNM staging incl. LN/distant met status if applicable

Other:

- Additional findings / diagnoses
- Commentary

References:

1. ***CAP protocols***
2. ***AJCC Handbook***

Synoptic reporting elements:

Histological subtypes:

- Main subtypes:
  - ***Superficial spreading*** = Invasive melanoma with radial +/- vertical growth phase (conventional type)
  - ***Nodular melanoma*** = Invasive melanoma with vertical growth phase only
  - ***Lentigo maligna melanoma*** = Invasive melanoma arising in sun-damaged skin with lentiginous pattern of in situ growth
  - ***Acral lentiginous melanoma*** = Invasive melanoma arising in subungual or acral skin with lentiginous pattern of in situ growth
  - ***Desmoplastic melanoma*** = Invasive melanoma with infiltrative growth pattern and spindle cell morphology; may be mixed with other subtypes
  - Others: Nevoid melanoma; Melanoma arising in a congenital nevus; Blue nevus – like melanoma

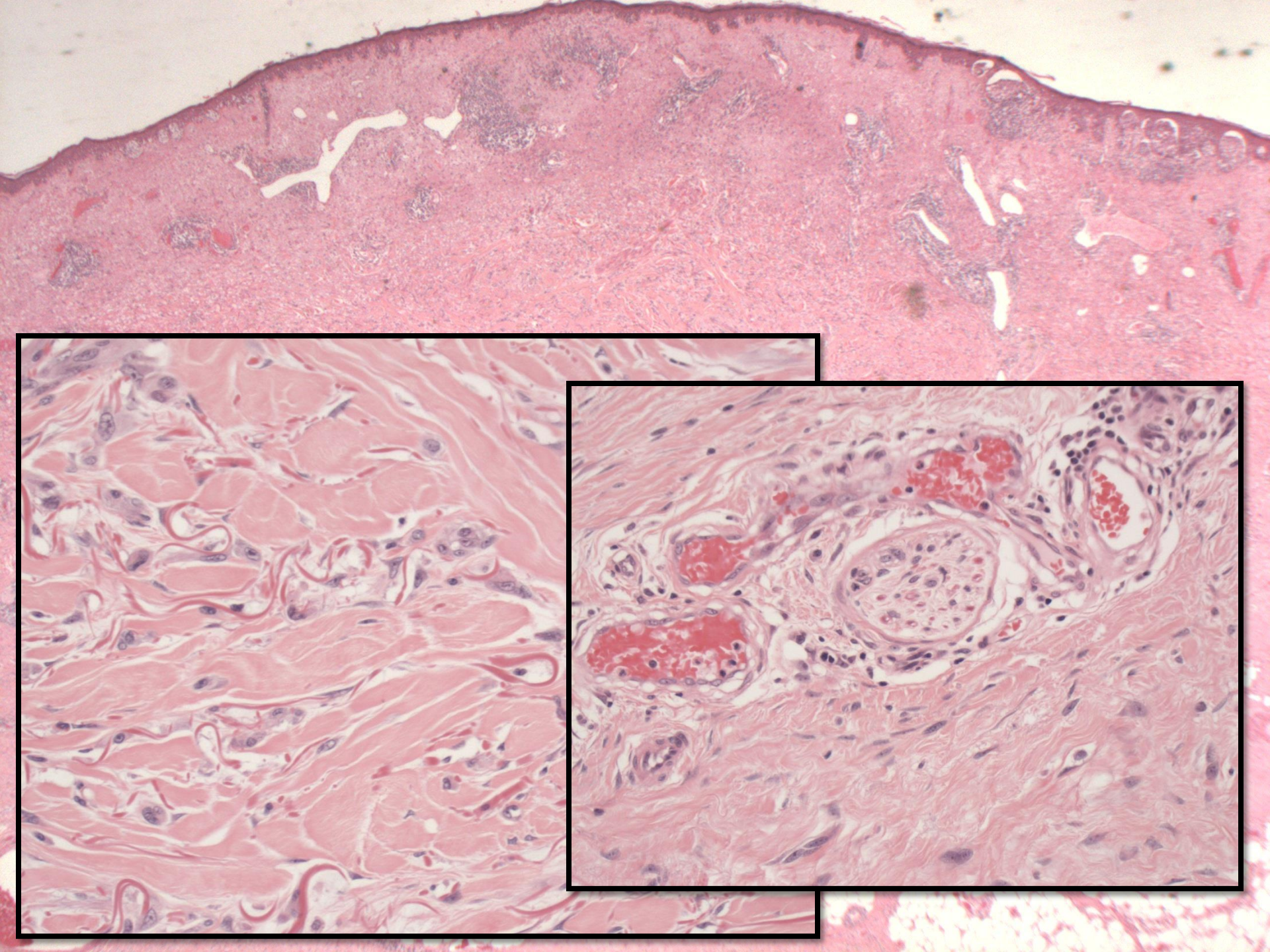

Synoptic reporting elements:

Staging parameters:

Breslow thickness: measurement from top of granular cell layer (or base of ulcer if ulcerated) to the deepest point of tumor invasion

Ulceration: full thickness epidermal defect resulting from tumoural destruction requiring:

- full-thickness epidermal defect (including absence of stratum corneum and basement membrane)
- evidence of reactive surface changes (e.g. surface fibropurulent exudate)
- thinning, effacement, or reactive hyperplasia of the surrounding epidermis
- absence of trauma or a recent surgical procedure

Mitotic index: count of dermal mitoses within 1mm2 of contiguous area of the tumour at its 'hot-spot' (i.e. area of highest mitotic activity)

Synoptic reporting elements:

Other histological features:

Regression: An area suggestive of tumour loss

- Dermal fibrosis and vascular proliferation (i.e. scarring)
- Complete or partial loss of tumor cells
- Lymphocytic inflammation
- Melanophagocytosis

Note: Complete regression or regression involving more than 75% is an adverse prognostic finding

Microsatellitosis: presence of discrete tumor nodules separated from the main tumour bulk (represents aborted lymphatic metastases)

- Must be greater than 0.05 mm in diameter
- Must be separated from main tumour by at least 0.3 mm
- Must be within 2cm of the main tumour otherwise termed "In-transit metastasis"

Note: Satellitosis / in-transit metastases affect N-staging.

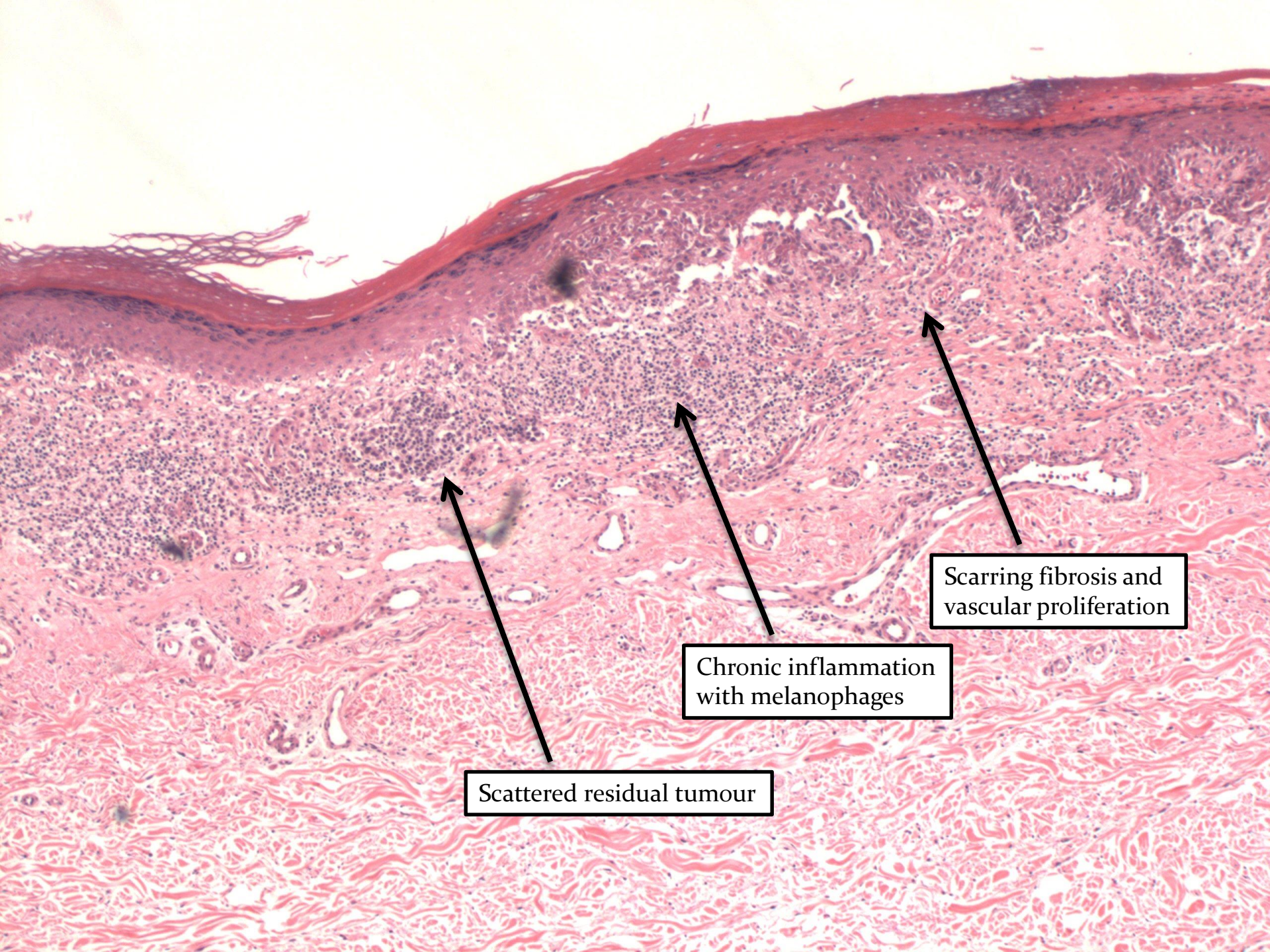
Scarring fibrosis and vascular proliferation
Chronic inflammation with melanophages
Scattered residual tumour

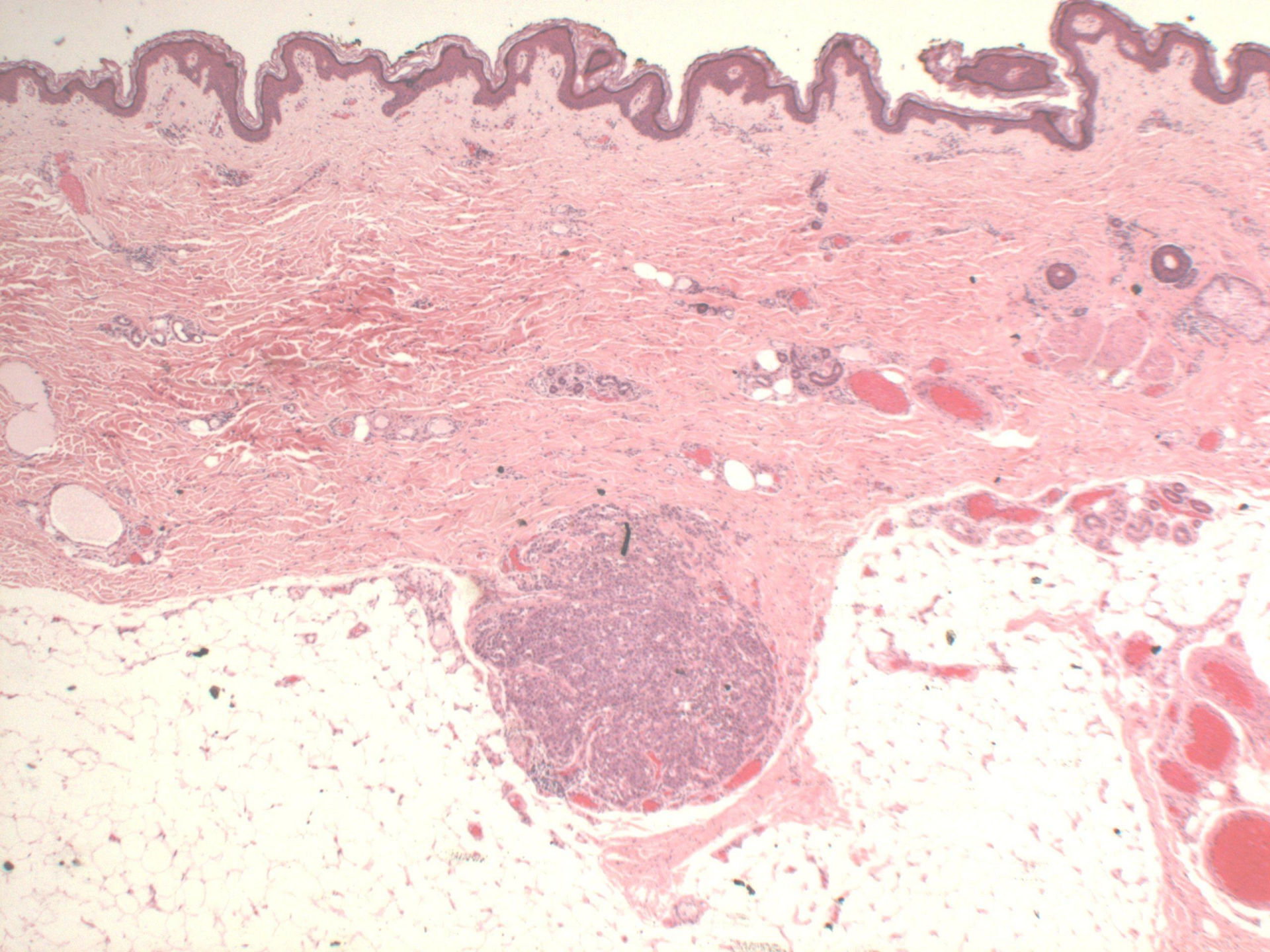

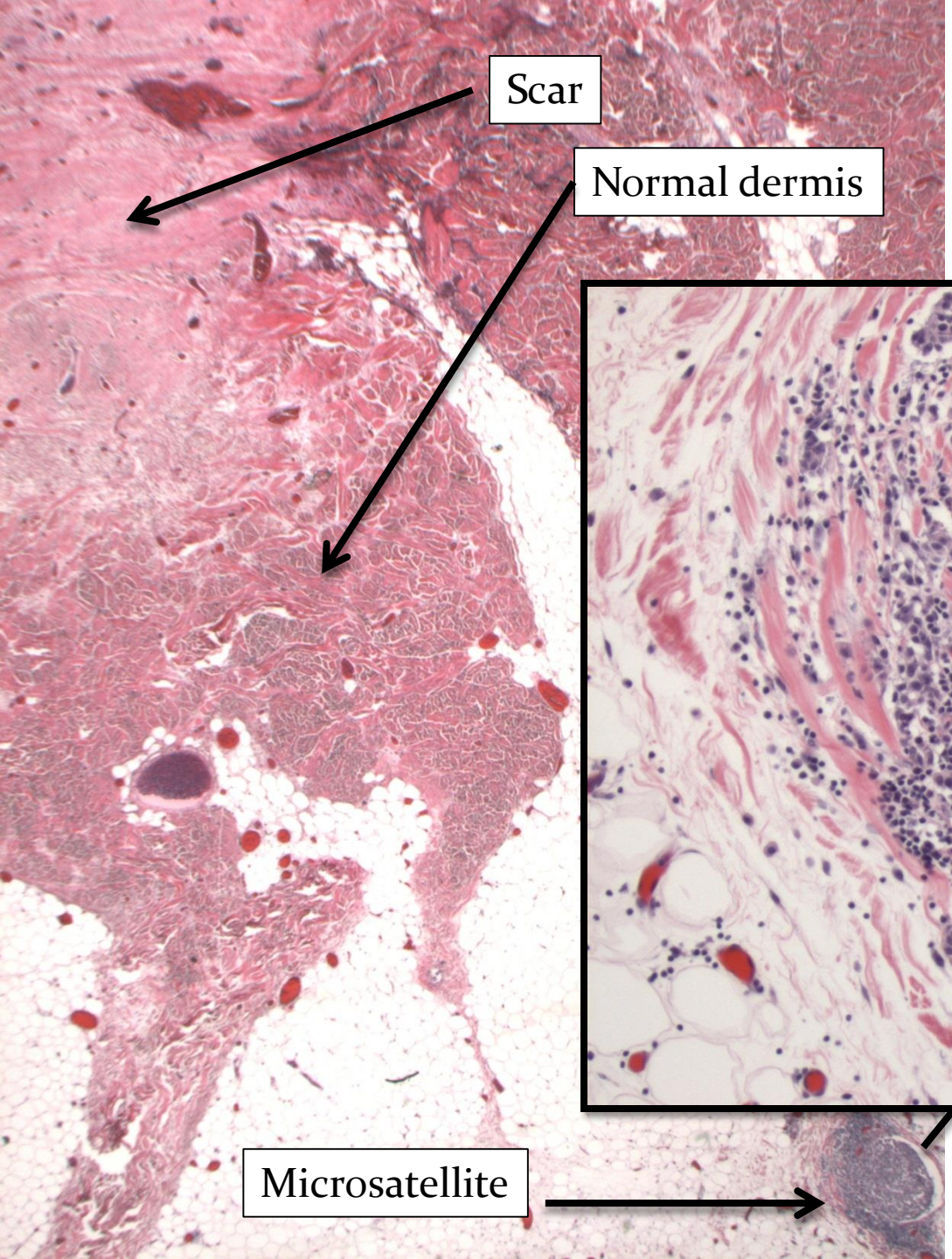

Staging = at least pN2c

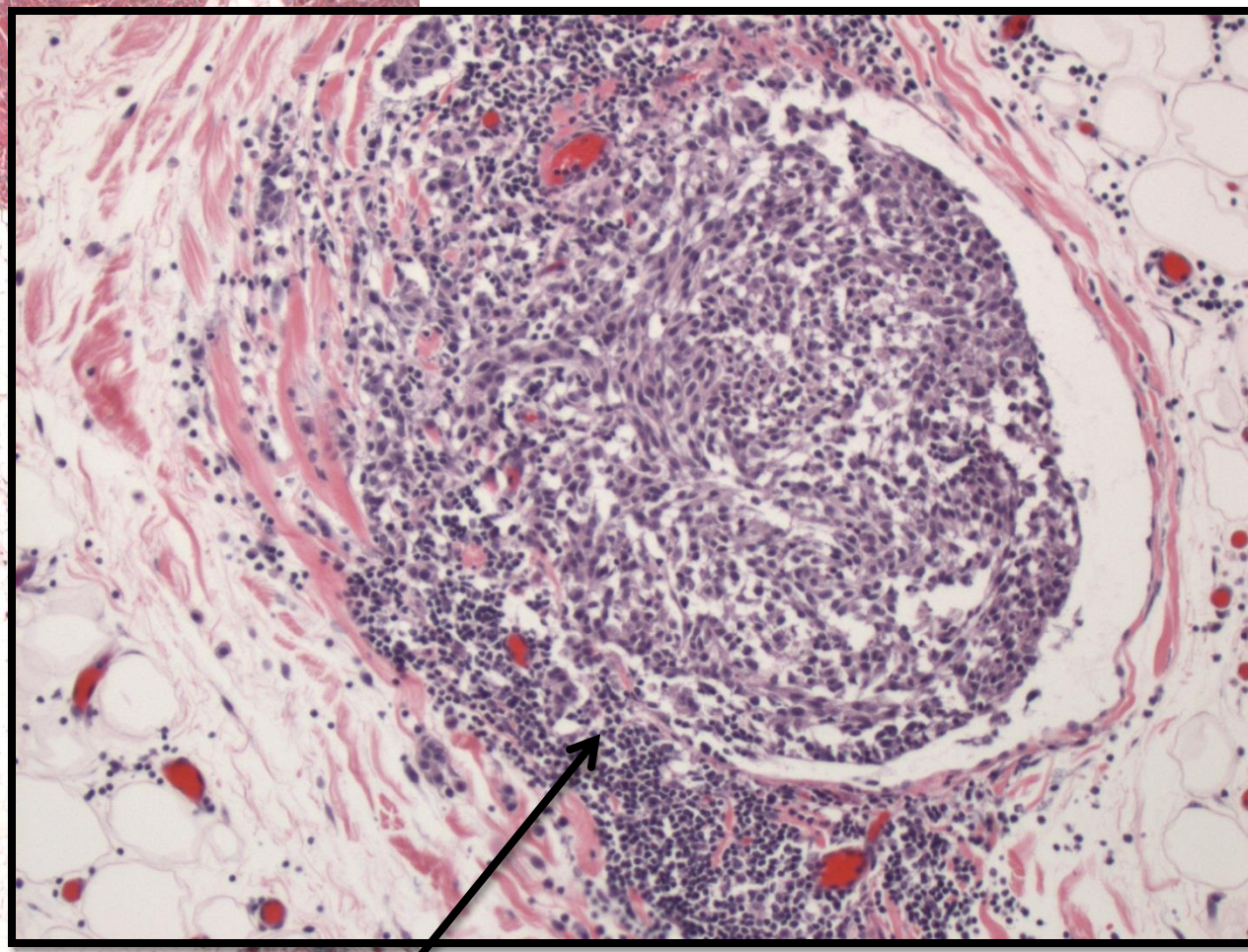

3 – Inflammatory dermatopathology

Inflammatory dermatopathology

Approach:

- Histological evaluation – try to key in on primary histopathological abnormality at low-power
  - Inflammatory vs Neoplastic vs Other
  - Epidermal changes vs Dermal changes only
    - Assess which is primary abnormality and which may be secondary findings
  - Define the pattern … this will suggest a DDx
  - Finer histological scrutiny to work through DDx
  - Ensure no missed secondary diagnoses or other pertinent findings and assess all required reporting details
  - Correlate with clinical data

Inflammatory dermatopathology

Main epidermal patterns:

- Spongiotic dermatitis
- Psoriasiform dermatitis
- Interface dermatitis
  - Vacuolar type
  - Lichenoid type
- Others: Acantholytic or other vesiculobullous; Abnormalities of keratinization

Dermal patterns: Urticarial reactions; Granulomatous incl. Palisaded granulomas; Other infiltrative disorders (dermal lymphocytic infiltrates; neutrophilic dermatoses; eosinophilic cellulitis); Vasculitic / vasculopathic; Dermal deposition disorders incl. Mucinoses; Alterations of stromal tissue; Disorders affecting adnexal structures; Panniculitis (subcutaneous pattern)

Spongiotic dermatitis

Patterns:
- Acute = prominent spongiosis, exocytosis and dermal edema / infiltrate but only minimal reactive epidermal changes
- Chronic = prominent chronic reactive epidermal changes (acanthosis, hyperkeratosis / parakeratosis) and variable spongiosis / exocytosis (may be largely resolved)
- Subacute = in between

Etiological considerations:
- Atopic dermatitis
- Contact dermatitis
- Drug reactions
- Arthropod bites / Parasitic infestations
- Superficial fungal infections
- Autoeczematization (Id rxn)
- Pityriasis rosea
- Others

Psoriasiform dermatitis

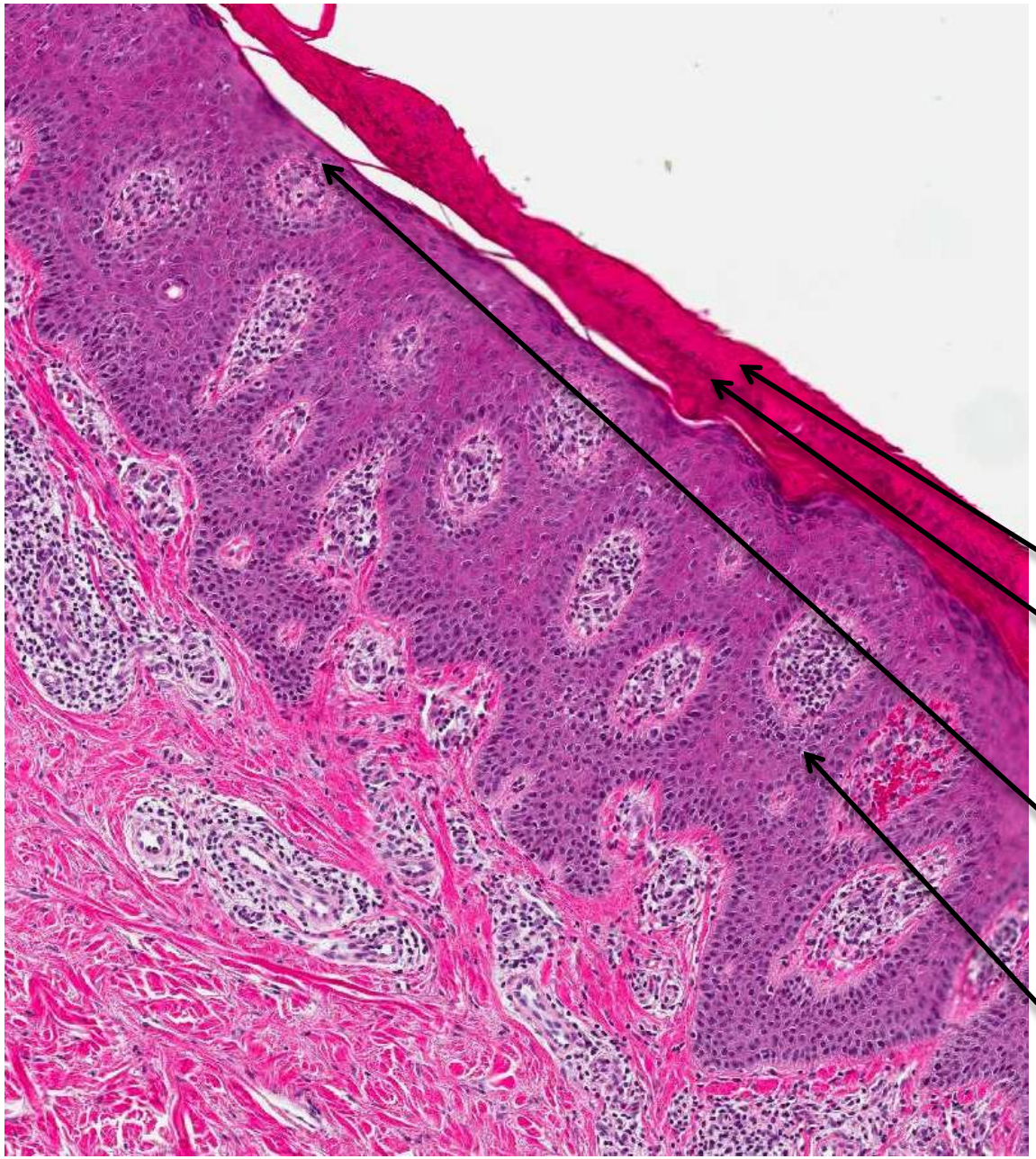

DDx:
- **Psoriasis**
- Chronic spongiotic dermatitis
- Psoriasiform drug eruption
- Seborrheic dermatitis
- Parapsoriasis
- Lichen simplex chronicus
- Pityriasis rubra pilaris
- Necrolytic erythemas
- Reiter's syndrome
- Bowen's disease
- Others

Confluent parakeratosis

Neutrophilic infiltration
- Stratum corneum
- Stratum spinosum

Thinning of suprapapillary plates

Regular 'psoriasiform' acanthosis

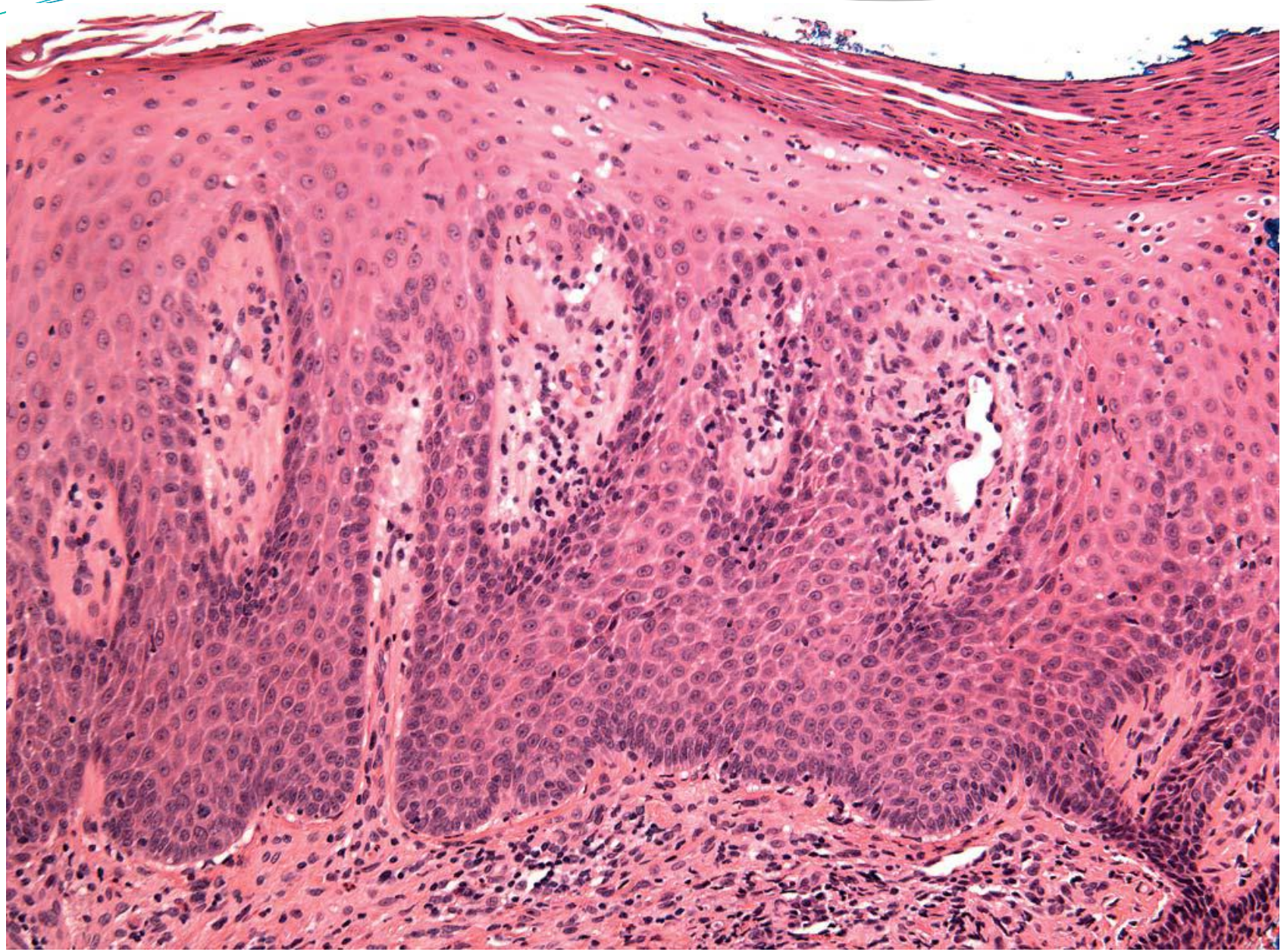

Vacuolar interface dermatitis

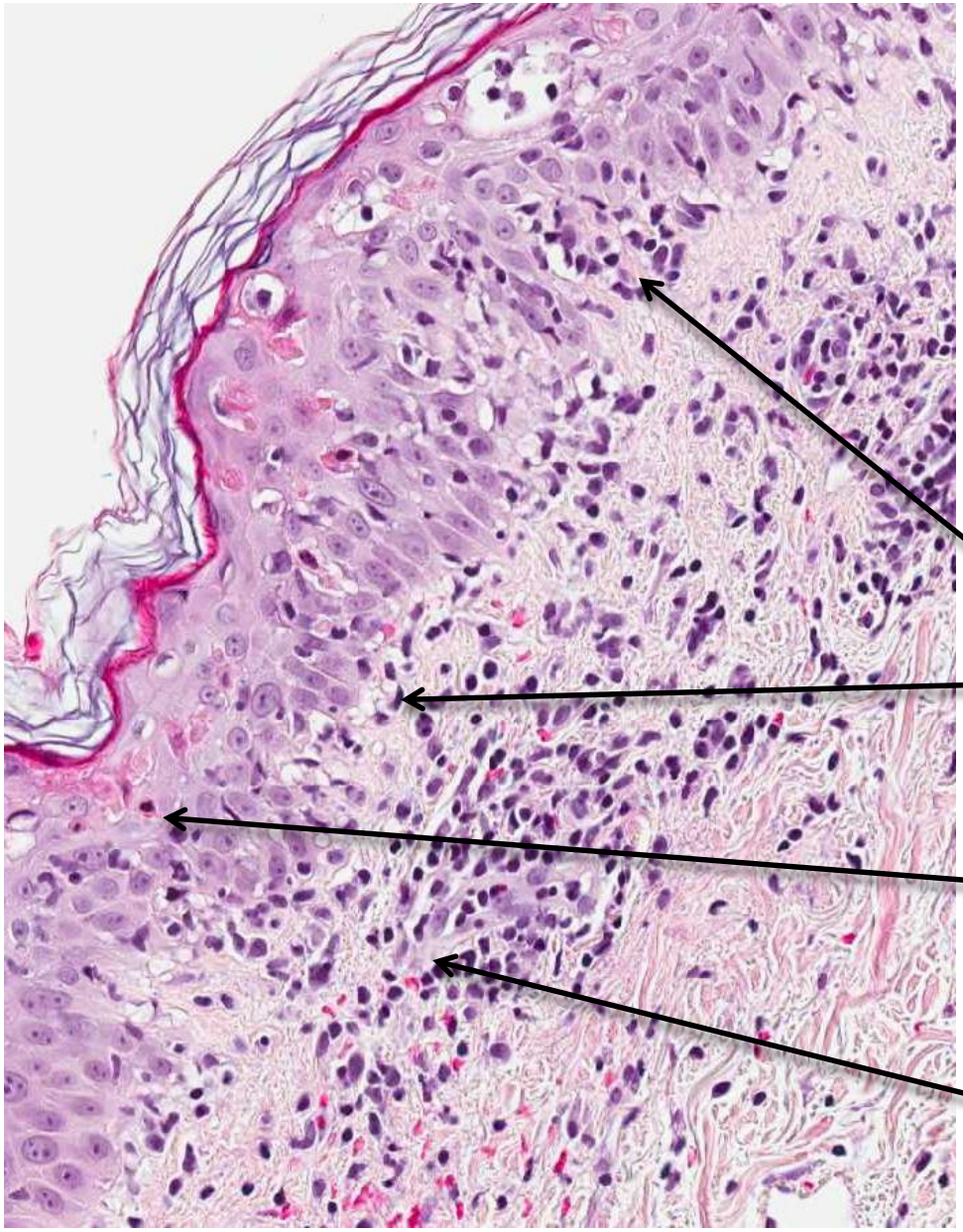

DDx:
- **Erythema multiforme**
- SJS / TEN spectrum disorder
- Lupus erythematosus
- Dermatomyositis
- Drug reactions / Fixed drug reaction
- Viral exanthem / HIV dermatitis
- Graft vs Host disease
- Pityriasis lichenoides
- Others

Interface inflammation

Vacuolar change to the basal cell layer

Keratinocyte necrosis
+/- "Satellite necrosis"
(generally basally oriented)

Variable perivascular
dermal inflammation

Lichenoid interface dermatitis

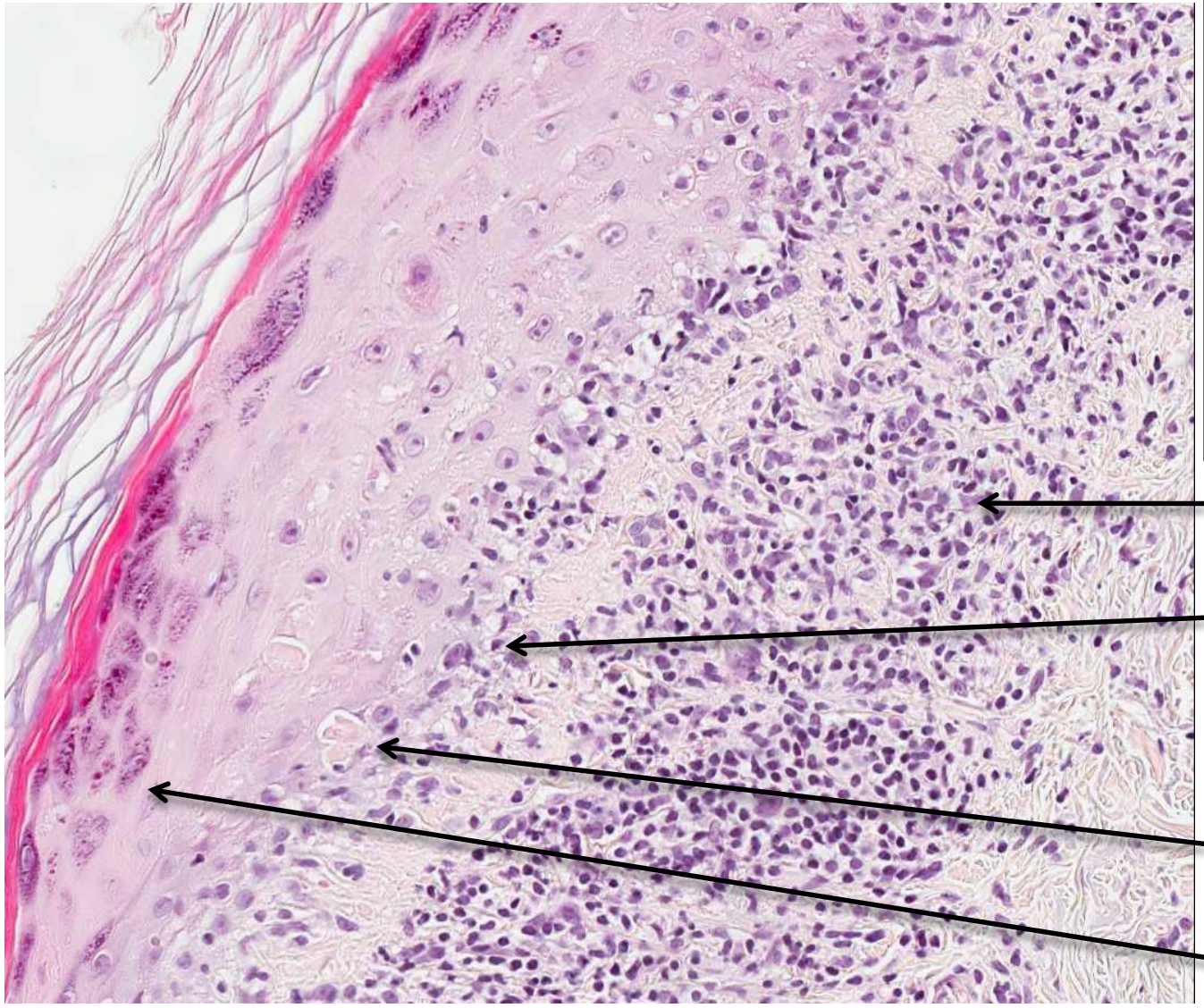

DDx:
- **Lichen planus**
- Lichenoid keratosis
- Lichenoid drug eruption
- Lichenoid pigmented purpura
- Lichen striatus
- Lichen nitidus
- Regression of neoplasms (e.g. Halo nevus; Regression in melanoma)
- Mycosis fungoides

Band-like inflammation

Interface activity and change incl. reactive "squamatization" of the basal cell layer +/- "saw-toothed" rete ridges

Necrotic keratinocytes / "Colloid bodies"

Reactive epidermal hyperplasia with hypergranulosis and hyperkeratosis

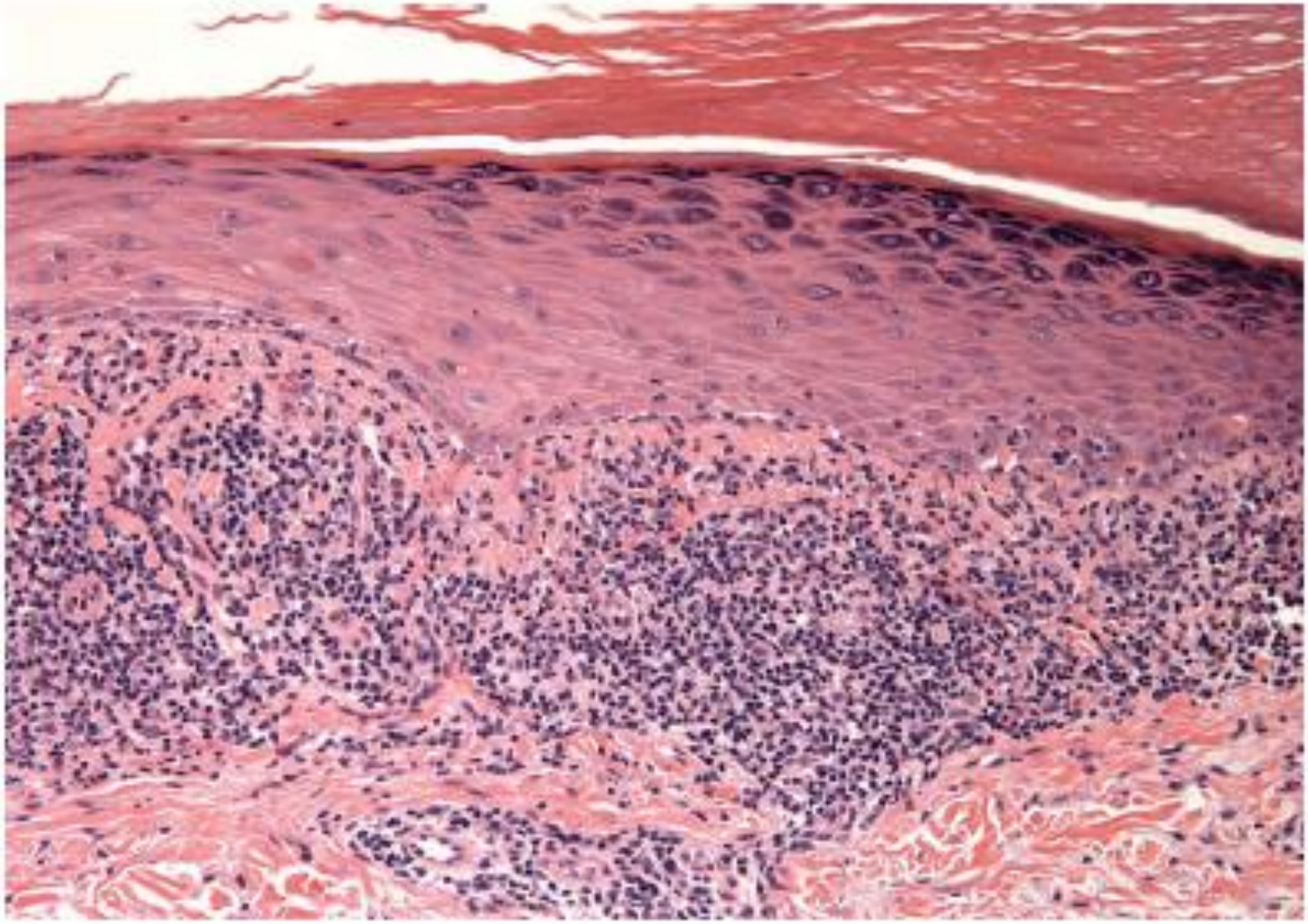

Summary

- Review / introduction of some of the common diagnosis in dermatopathology
- Focus on some of the DDx challenges and specific practice points / pitfalls
- Develop an approach to melanocytic lesions and understand synoptic reporting elements for melanoma.
- Introductory approach to inflammatory dermatopathology including diagnostic features for the archetypes for 4 common epidermal inflammatory patterns

Questions?



Comments?